

Ultrasound of the Neck

www.headandneckultrasound.co.uk

Rhodri M Evans



Ultrasound.

- Rules
- Lumps – cysts and nodes.
- Needles.

Lumps and bumps.

T

0 ◆

1 ◆

2 ◆

3 ◆

MI: 1.6

2DG

81

DR

60

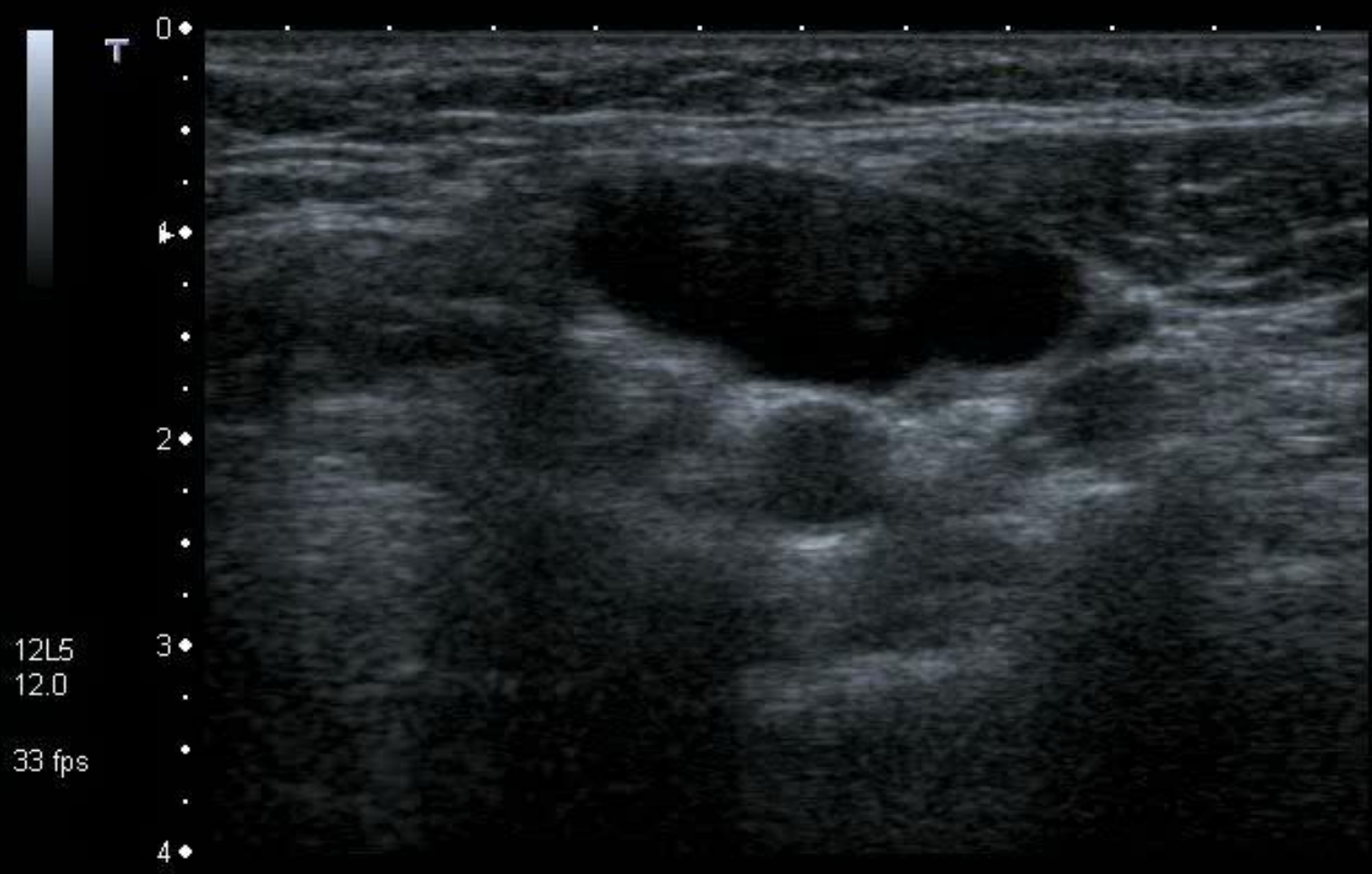
12L5

T9.0

16 fps

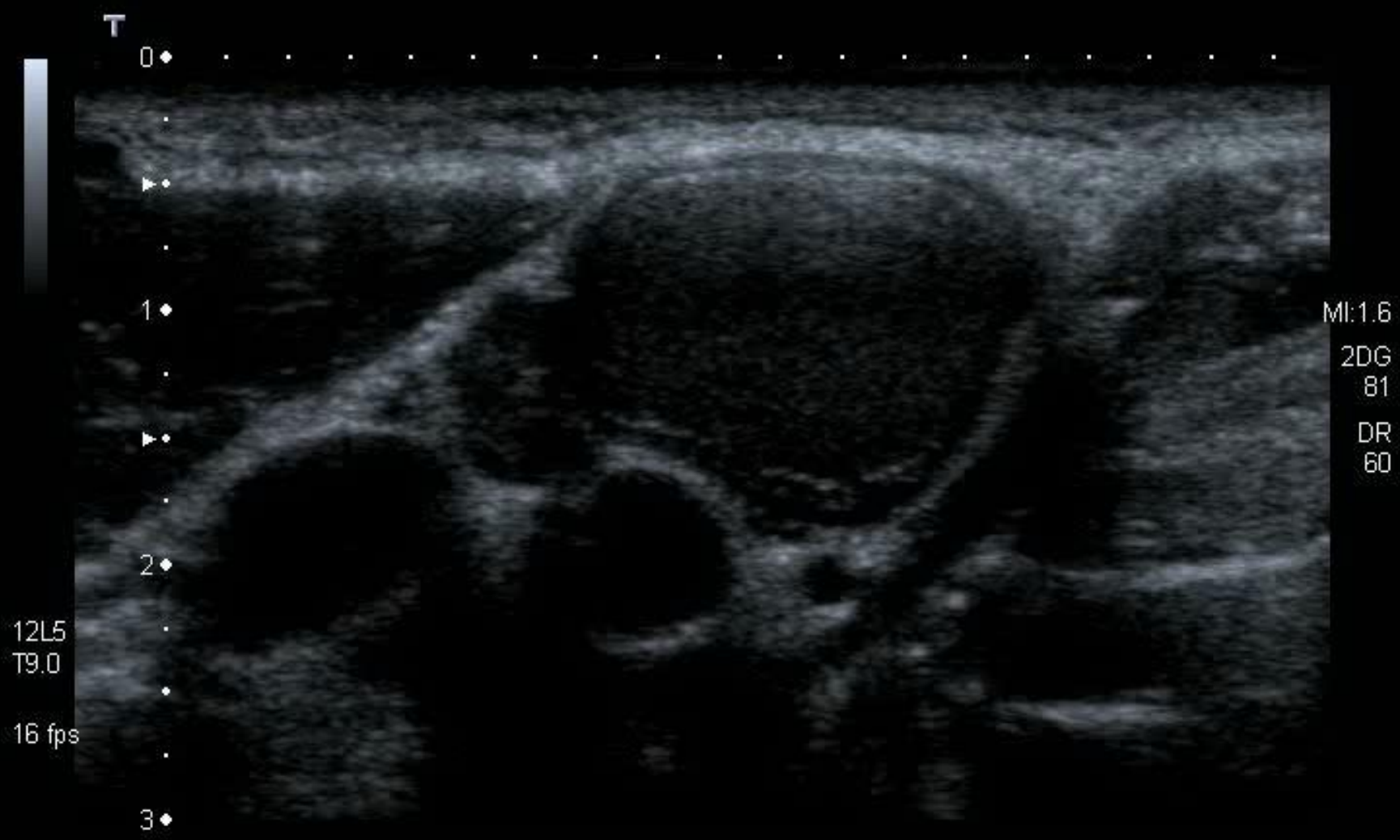
HDD: 90% Free

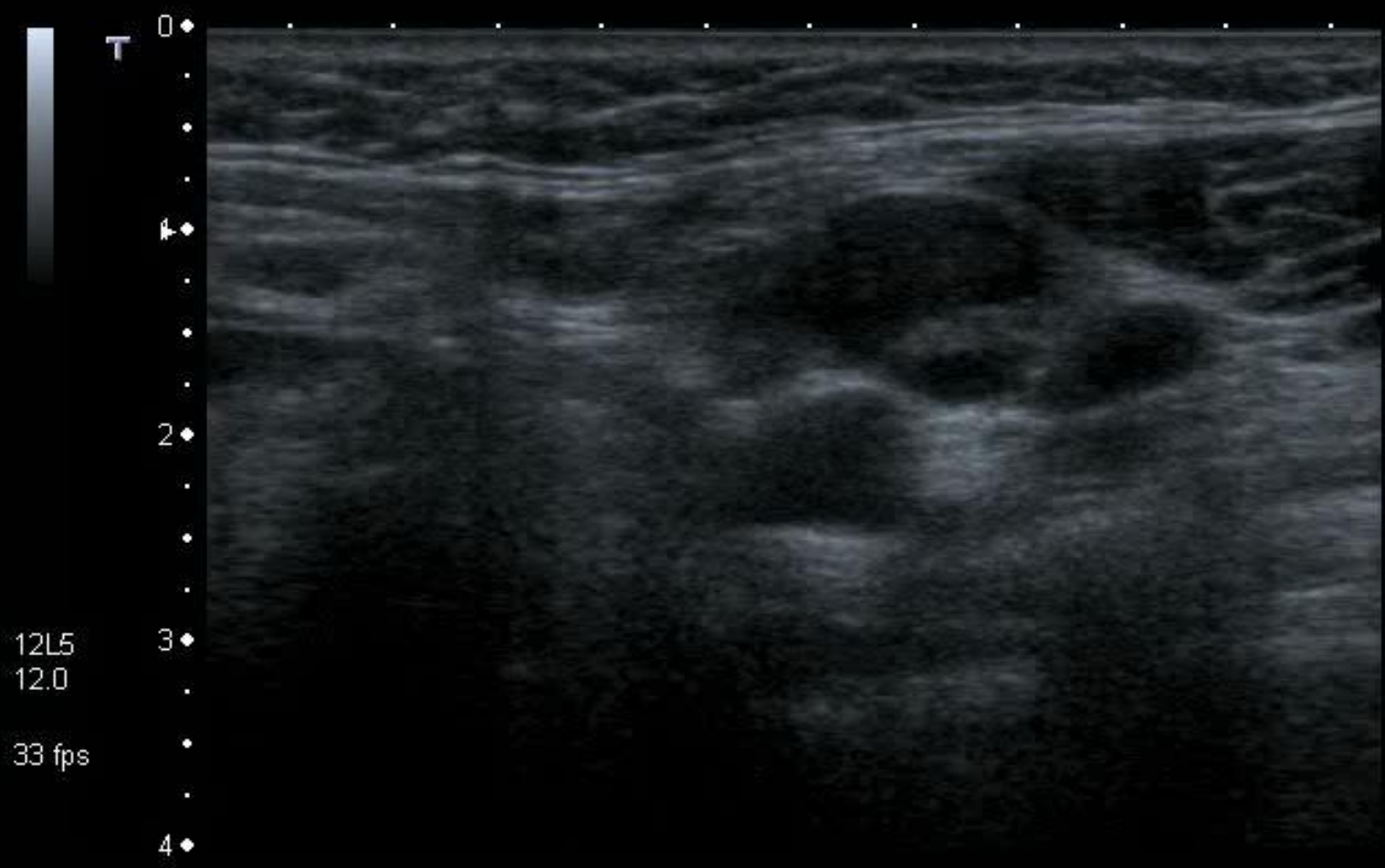




MI:0.5
2DG 81
DR 60

12L5
12.0
33 fps





12L5
12.0
33 fps

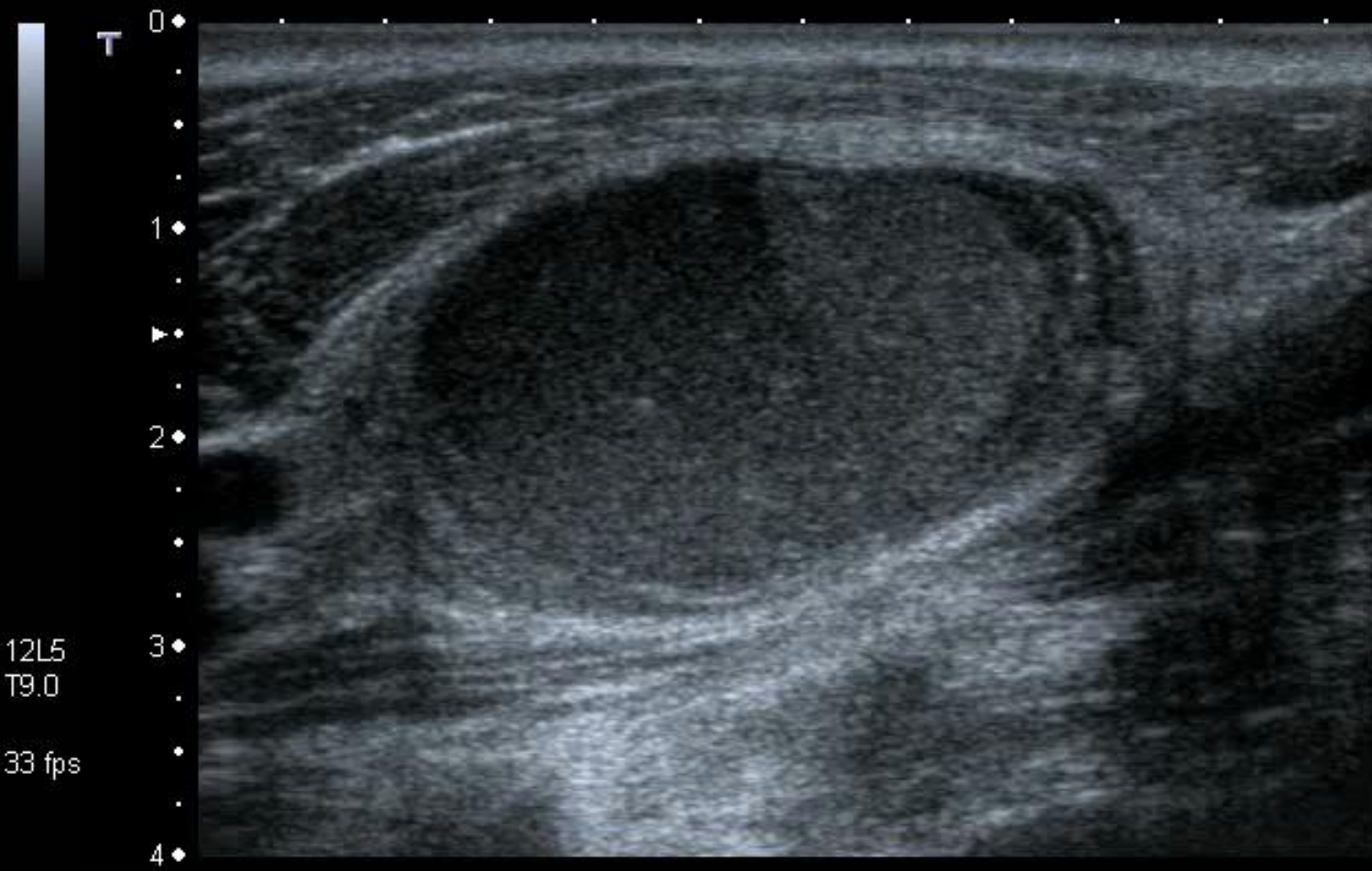
MI:0.5
2DG
81
DR
60

Rules .

- Cysts look solid.
- Solids can look cystic.

Rules .

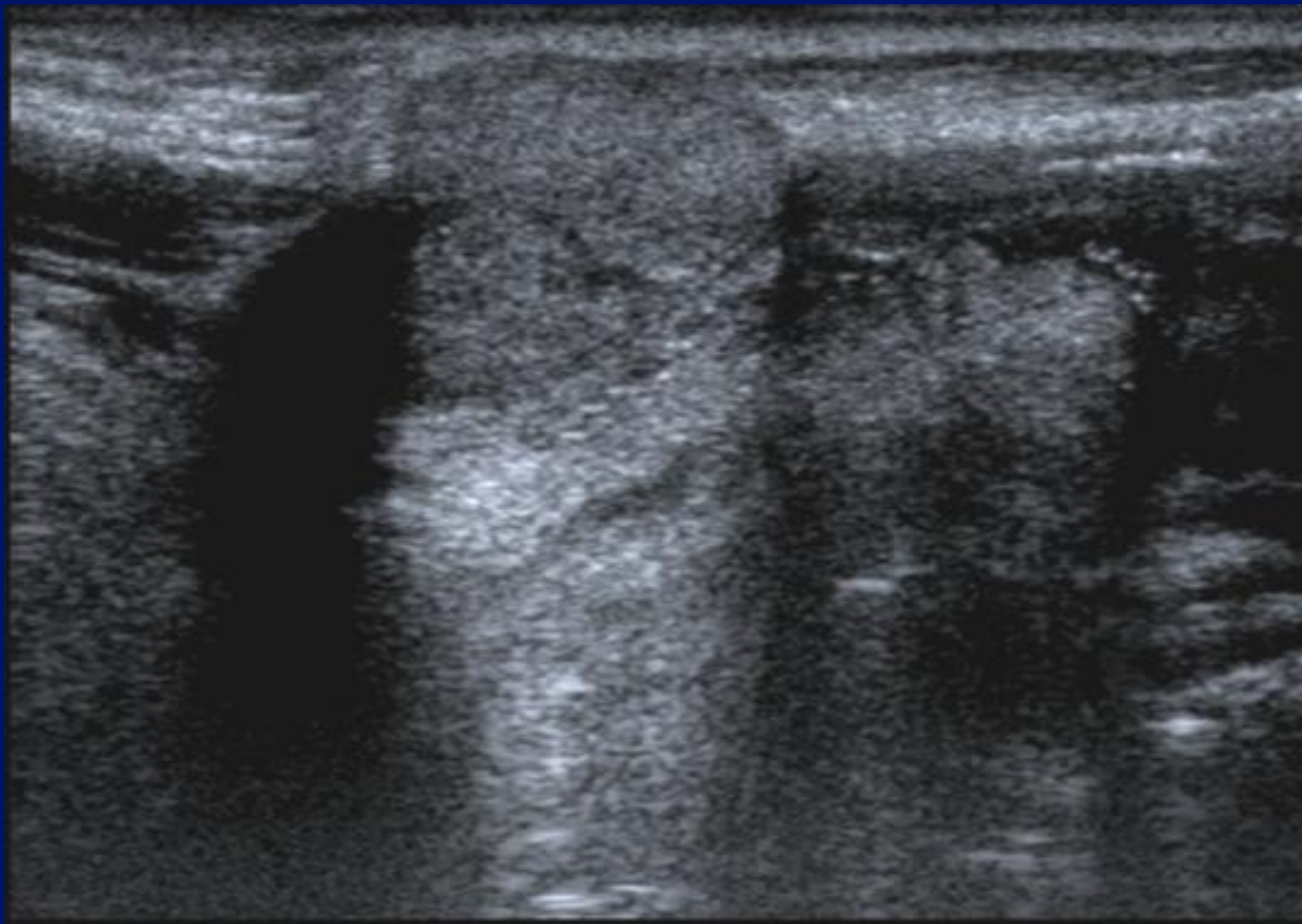
- Cysts don't usually look like cysts.
- Cysts will invariably look solid.
- If a mass looks cystic, it probably won't be a cyst.
- Solids can look cystic

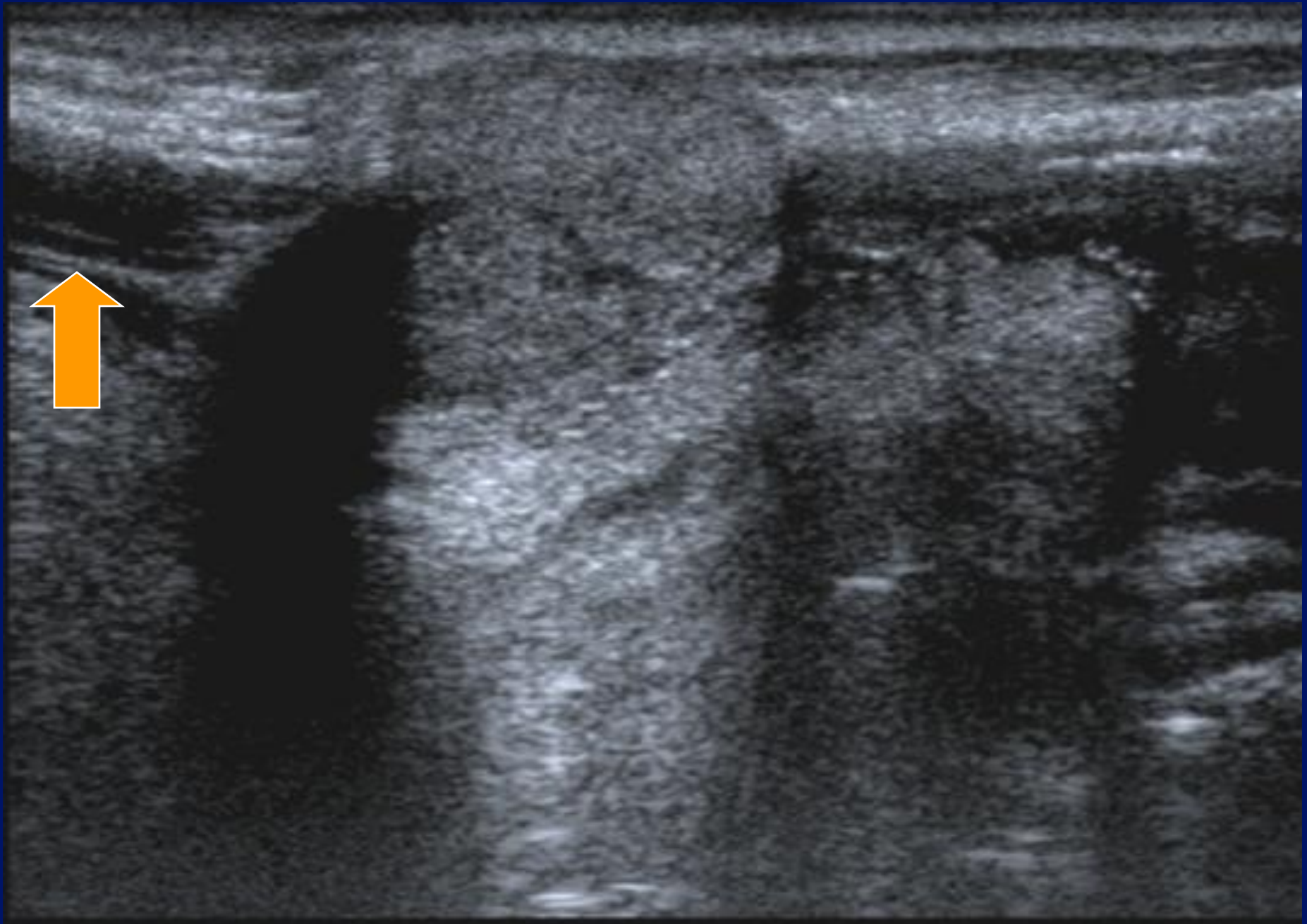


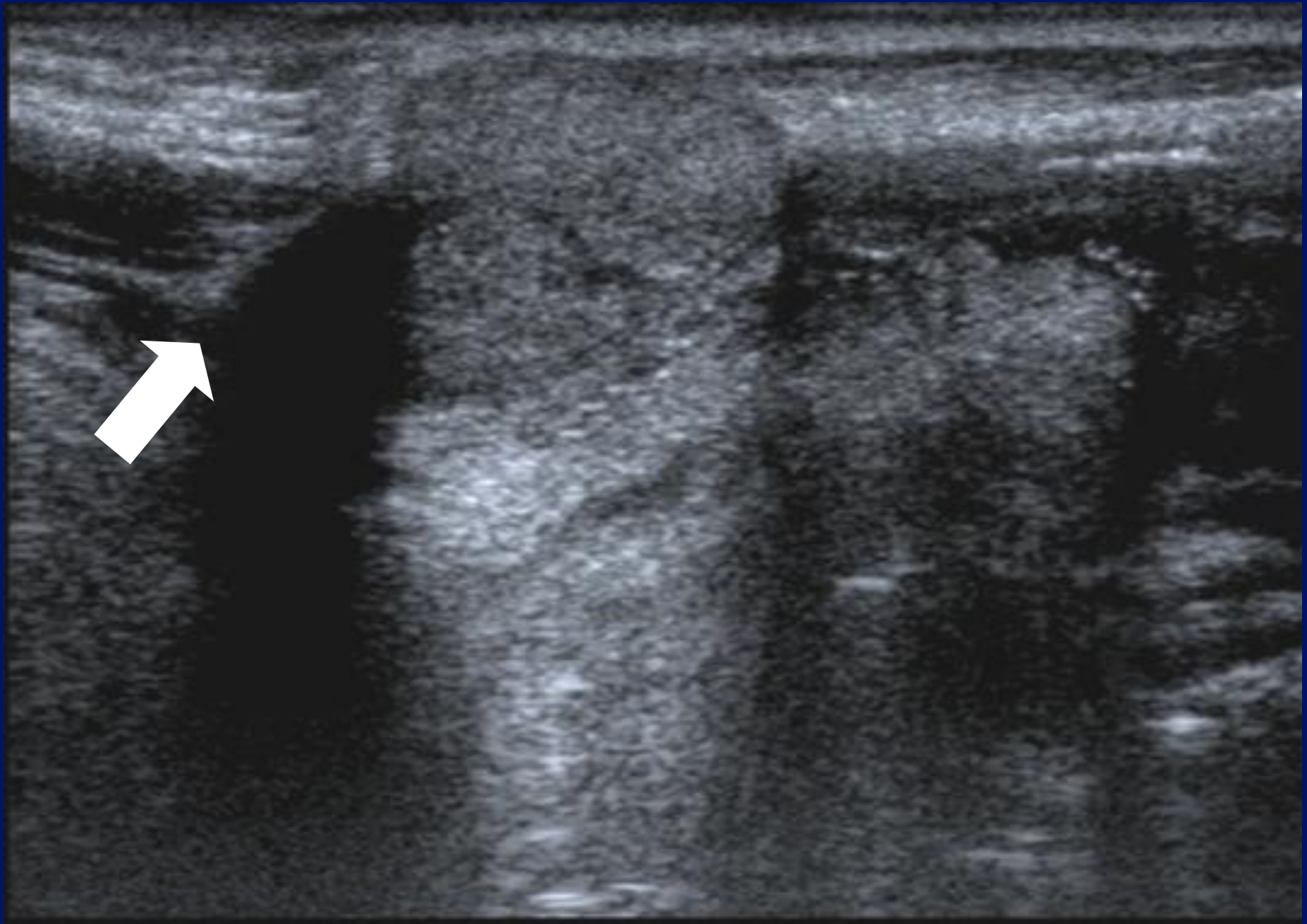
12L5
T9.0

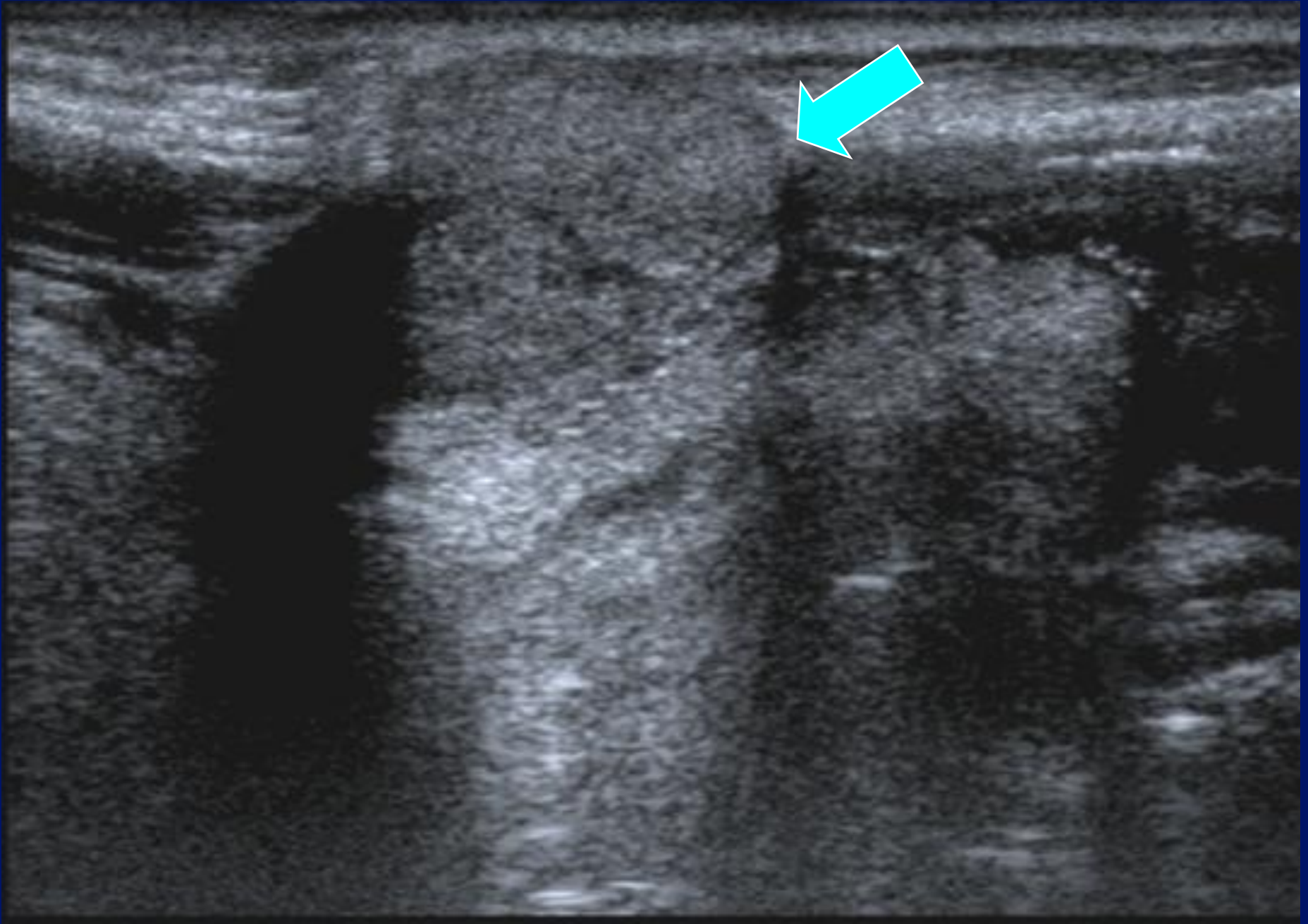
33 fps

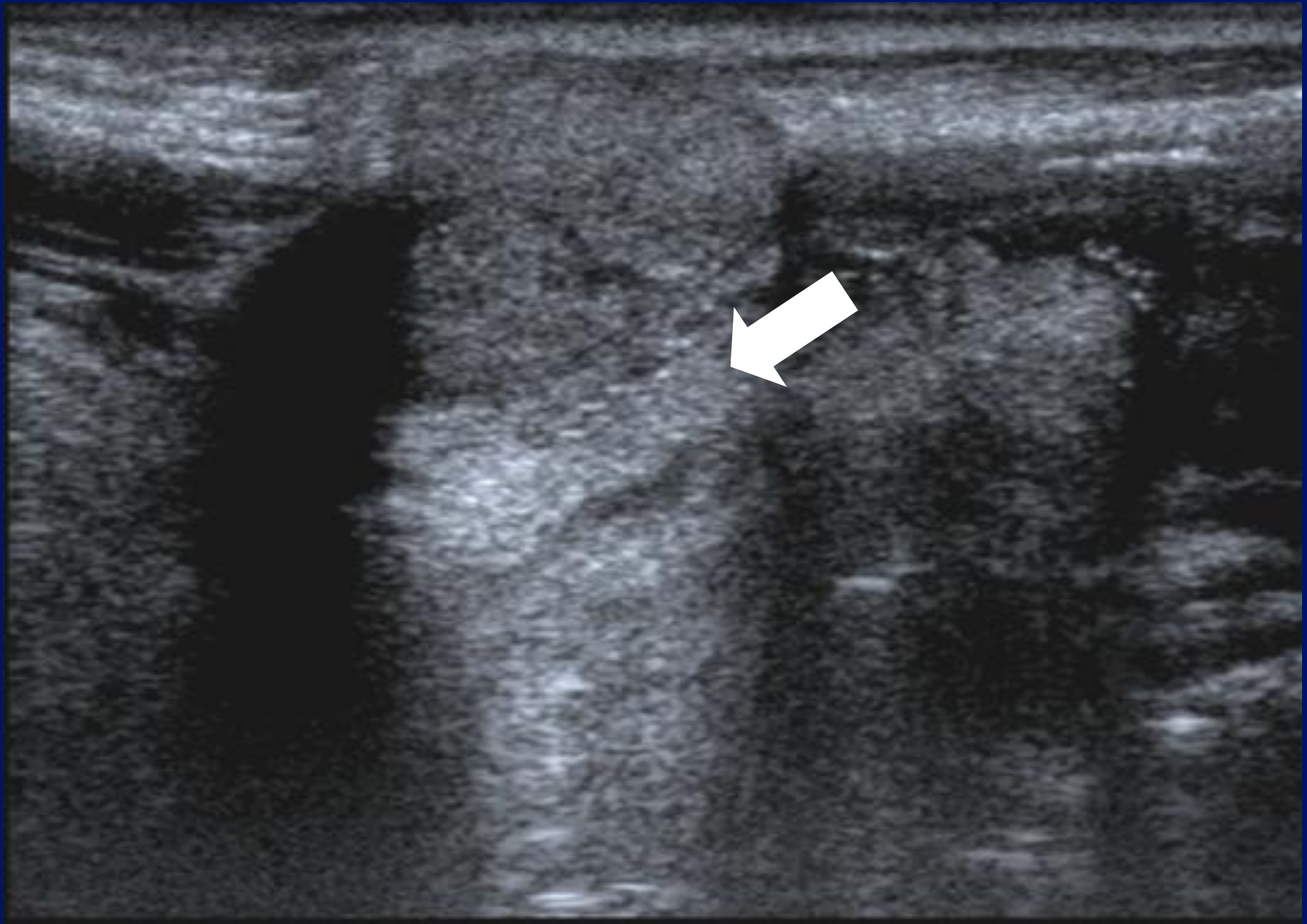
MI: 1.6
2DG
80
DR
70

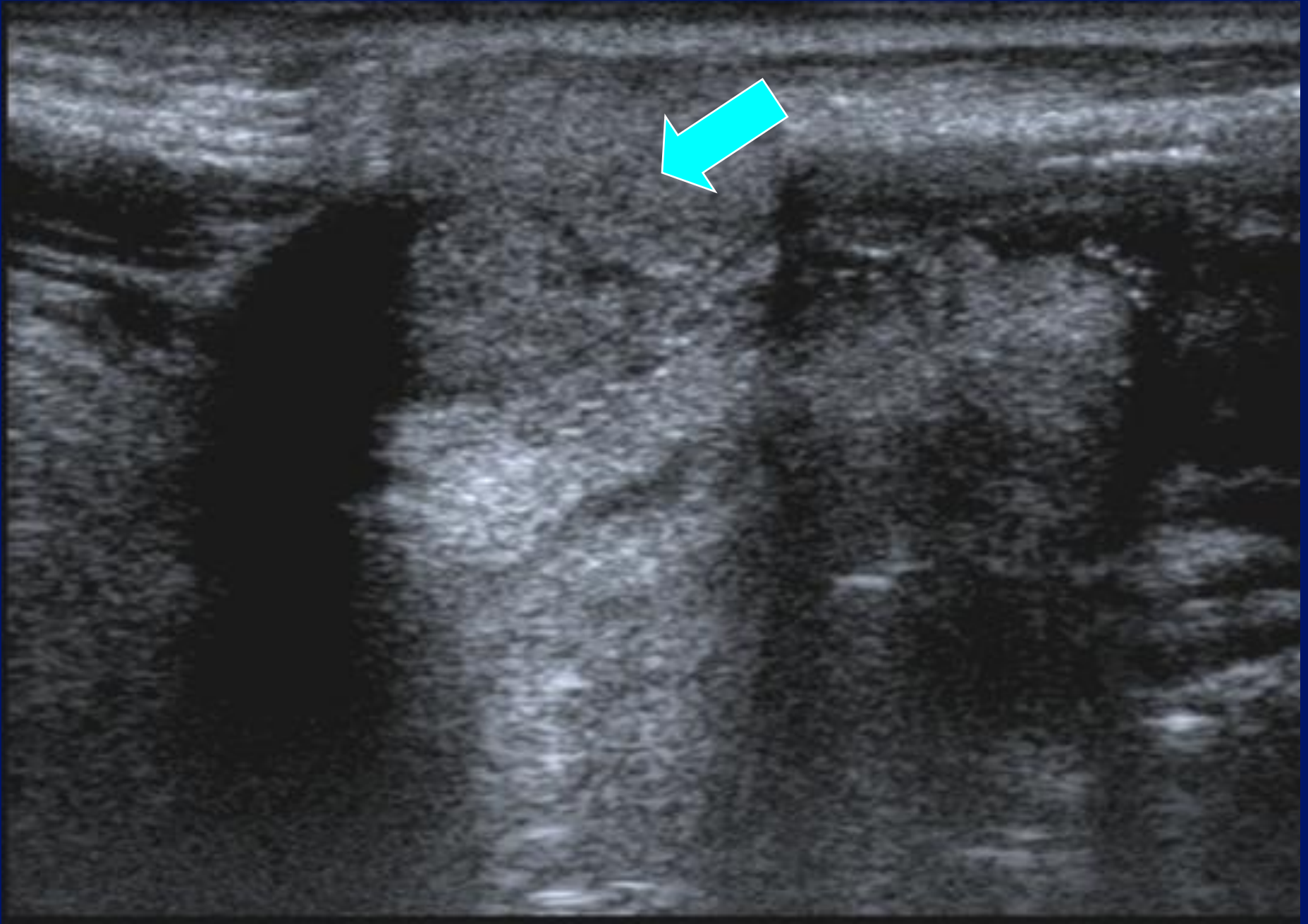


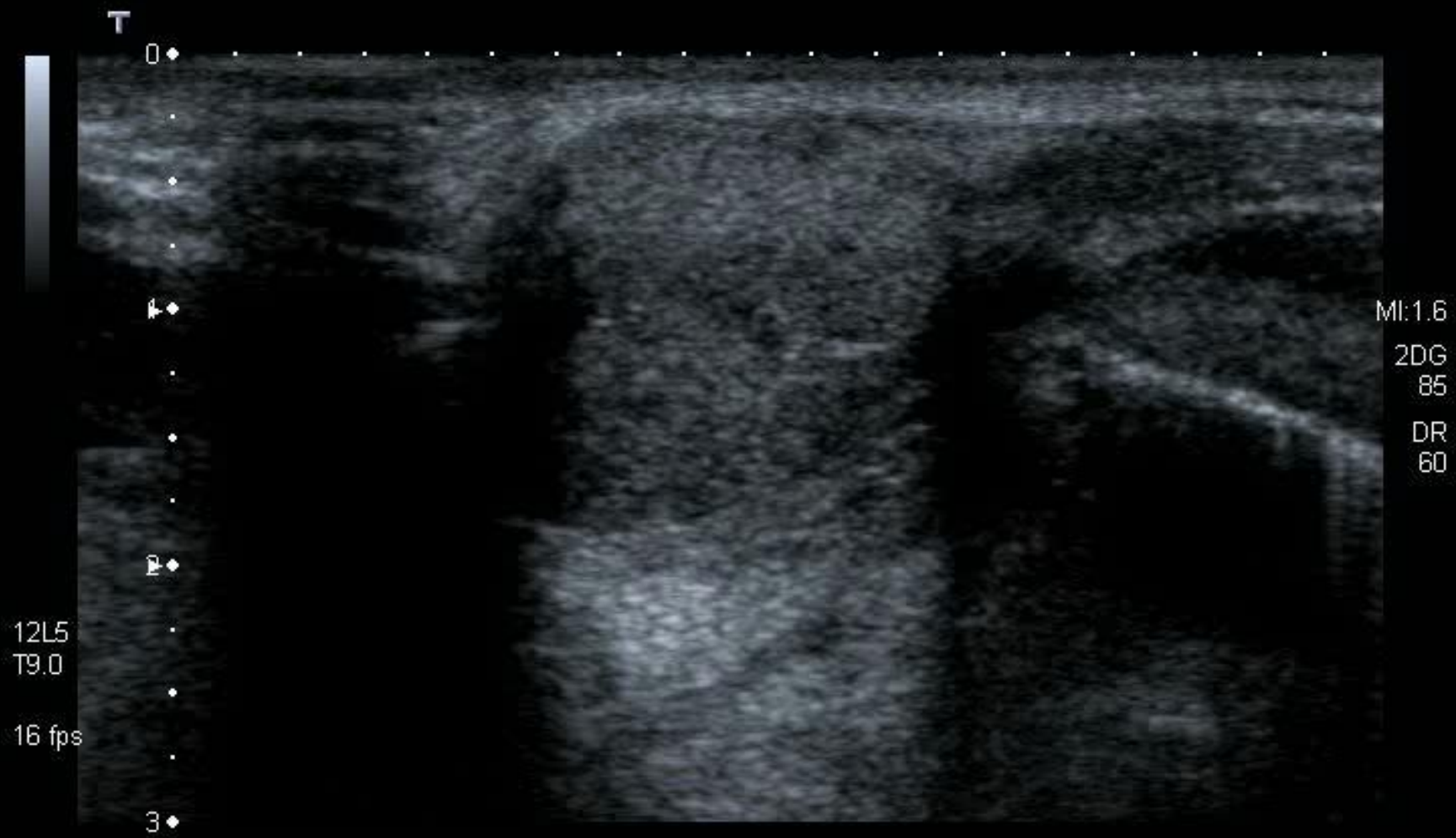














Rules .

- Cysts don't usually look like cysts.
- Cysts will invariably look solid.
- If a mass looks cystic, it probably won't be a cyst.
- Solids can look cystic

Cystic?




Pseudo-cystic?




Pseudo-cystic?

- Lymphoma.
- Pleomorphic adenoma.
- Nerve sheath tumour.
- Parathyroid adenoma.


Normal lymph nodes.



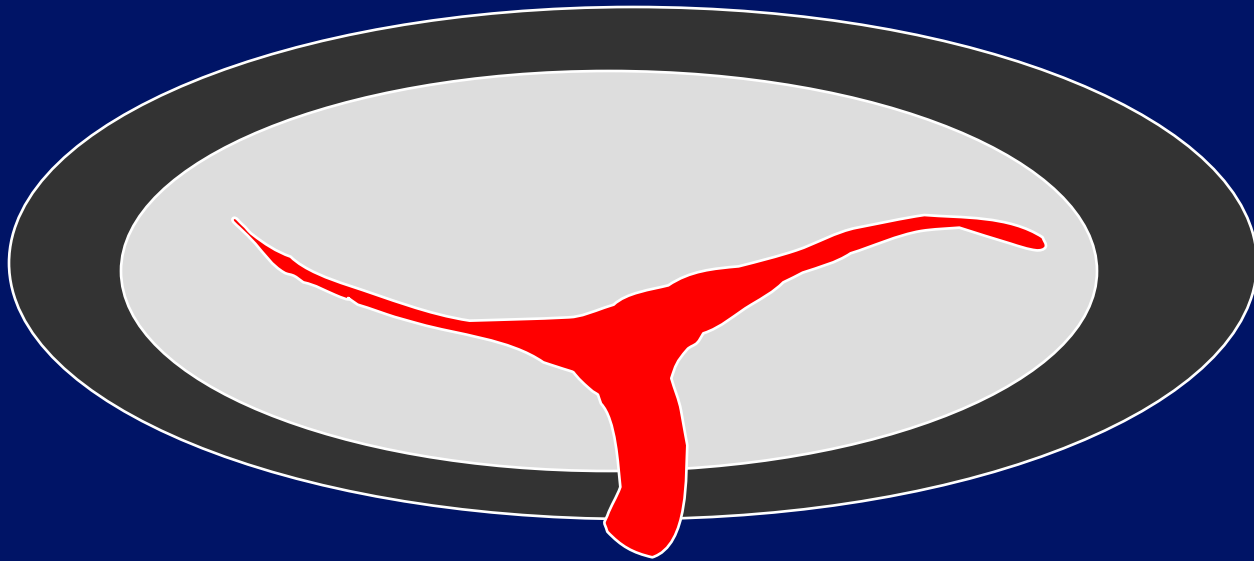
Normal lymph nodes.




Normal lymph nodes.




Normal lymph nodes.




Lymphoma?




Lymphoma




Metastatic lymph nodes



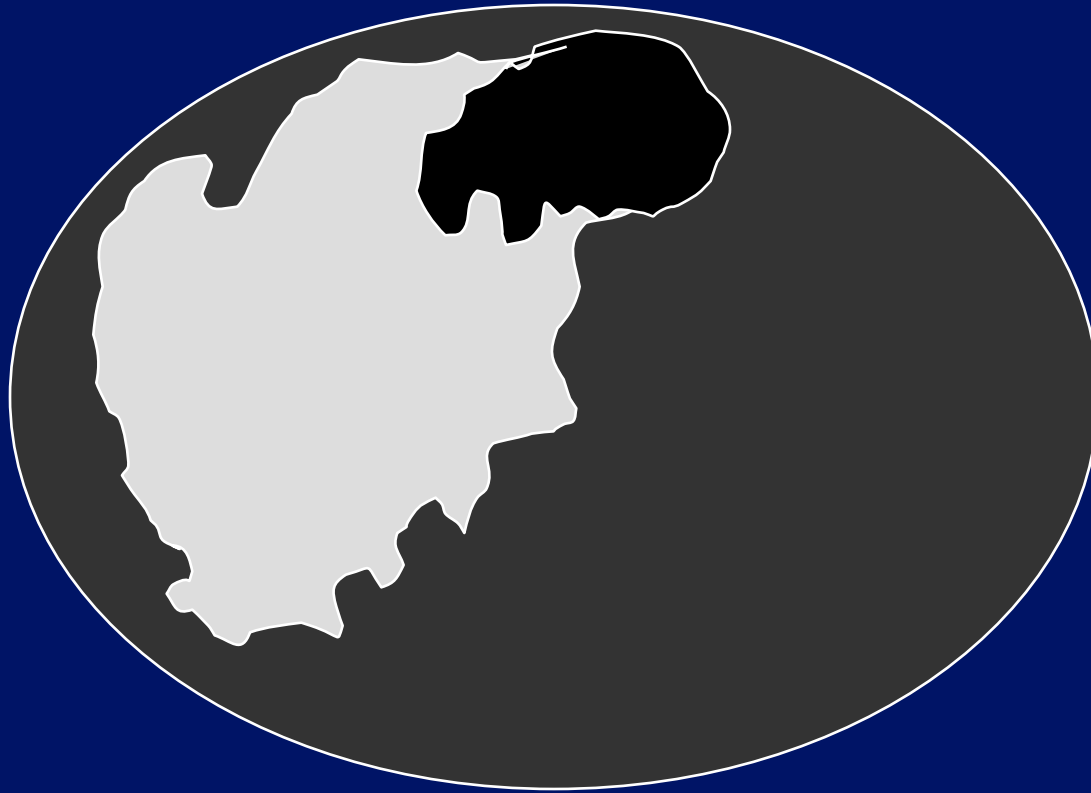
Malignant lymph nodes.



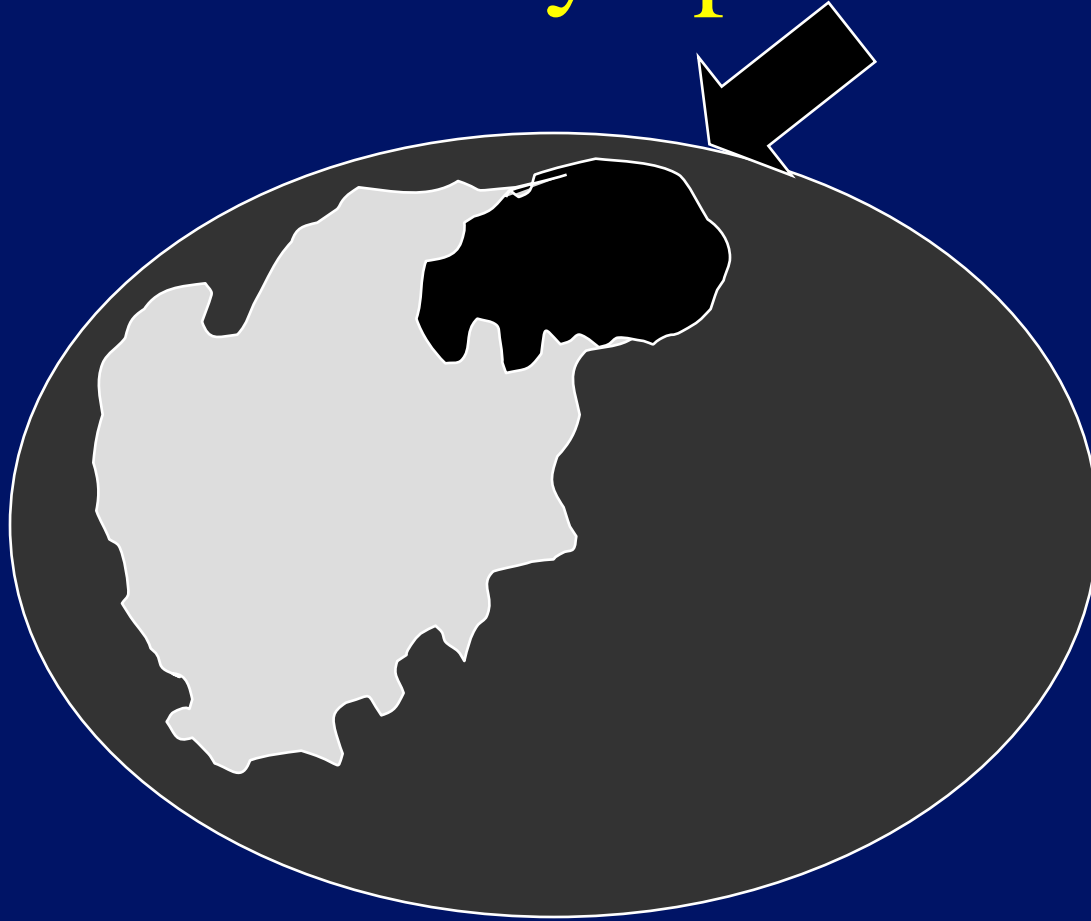
Metastatic lymph nodes




Metastatic lymph nodes



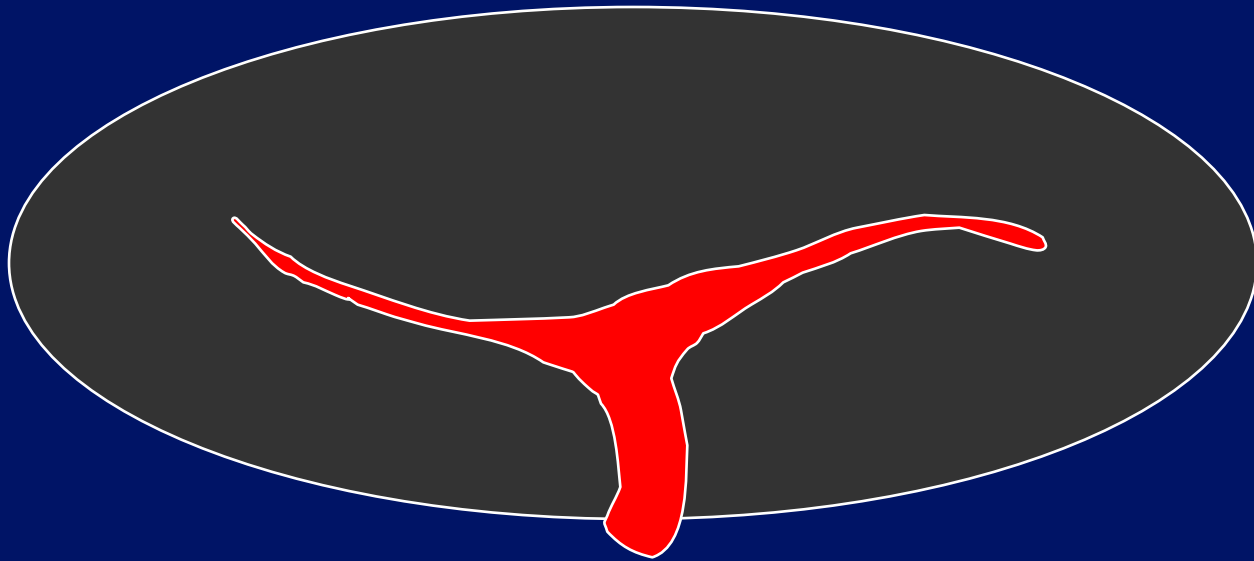
Metastatic lymph nodes




Normal lymph nodes.



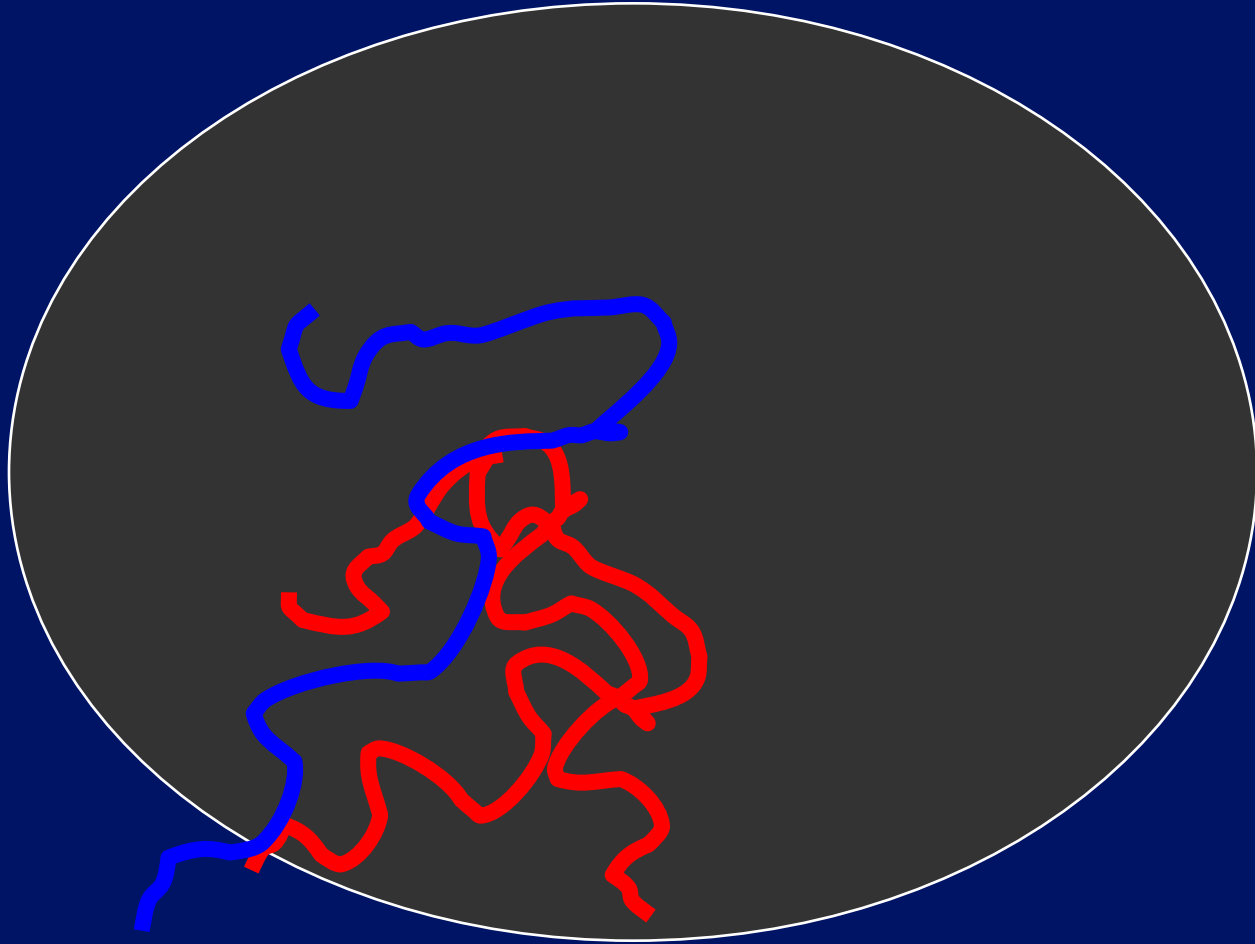
Normal lymph nodes.



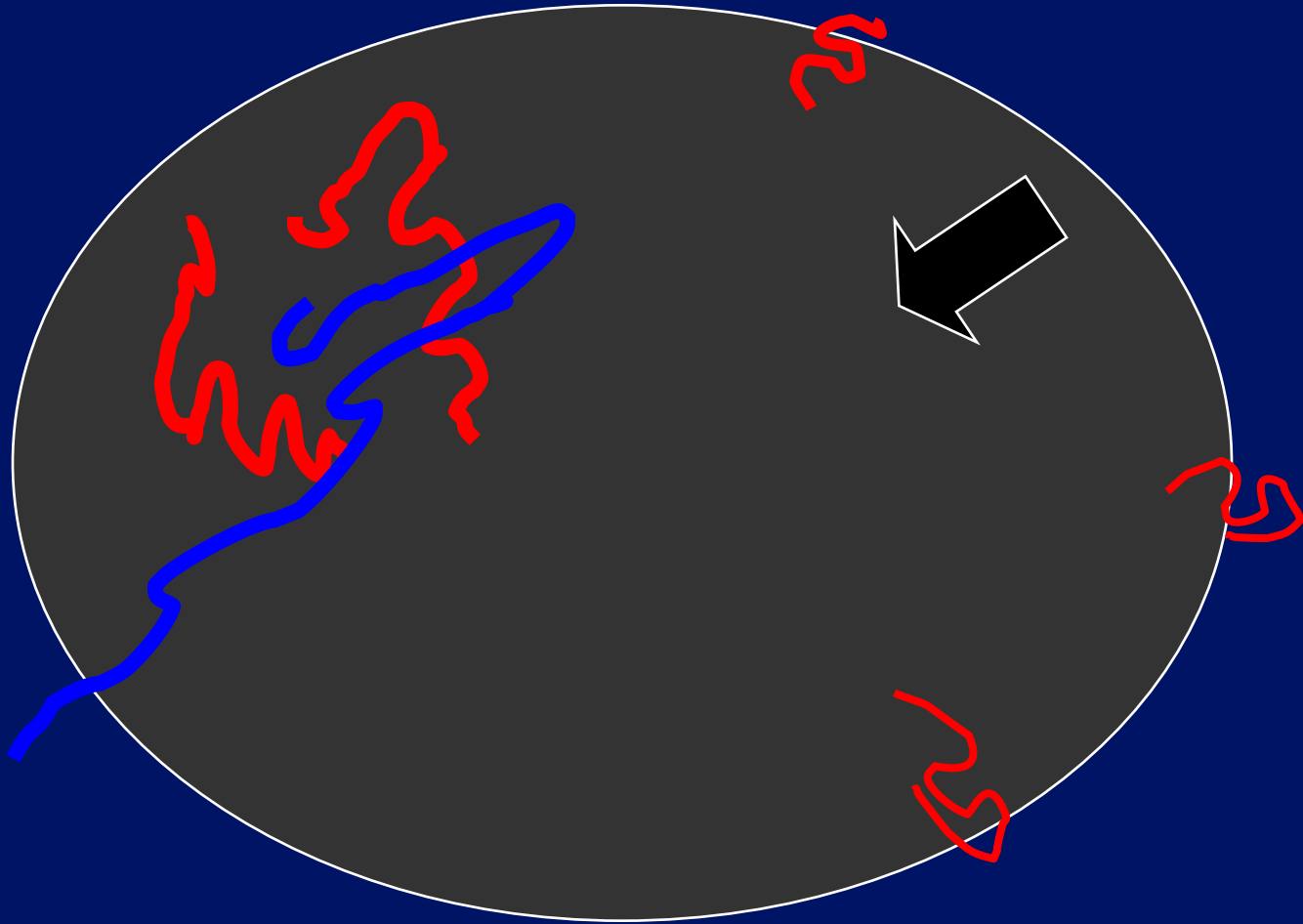
Malignant lymph nodes.



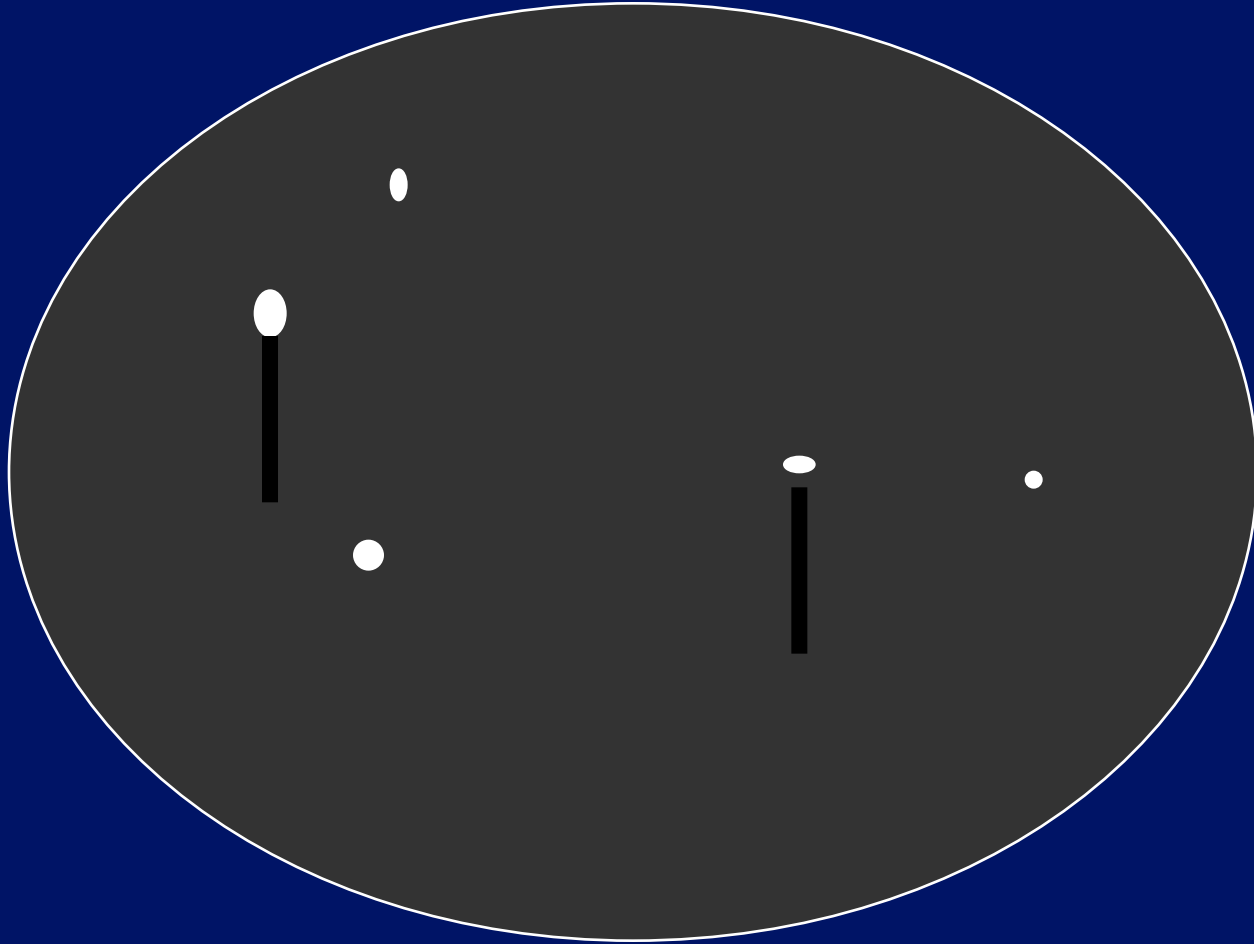
Malignant lymph nodes.



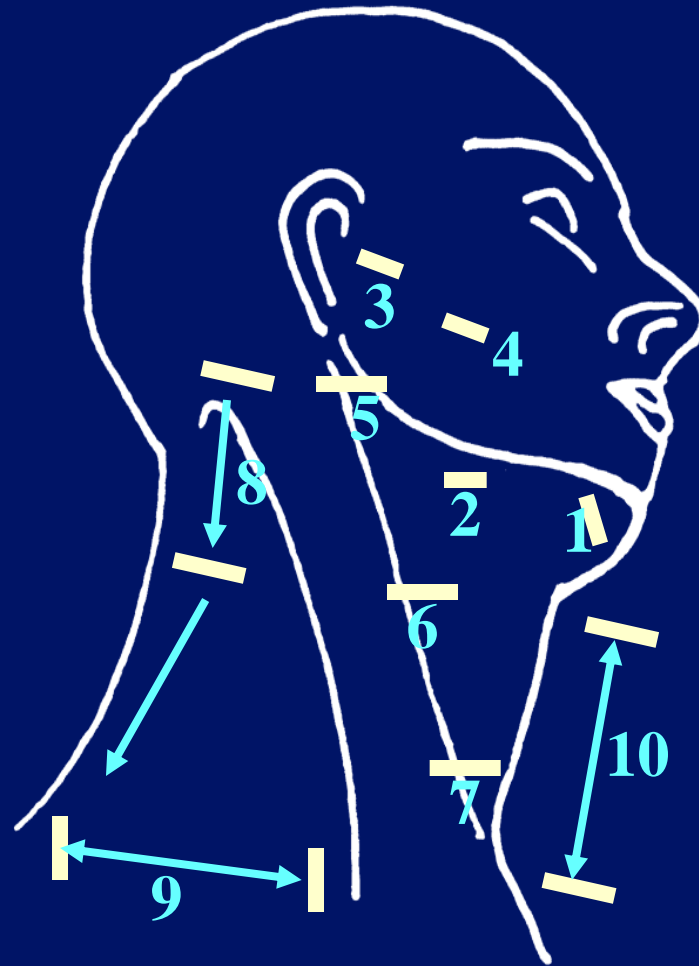
Malignant lymph nodes.



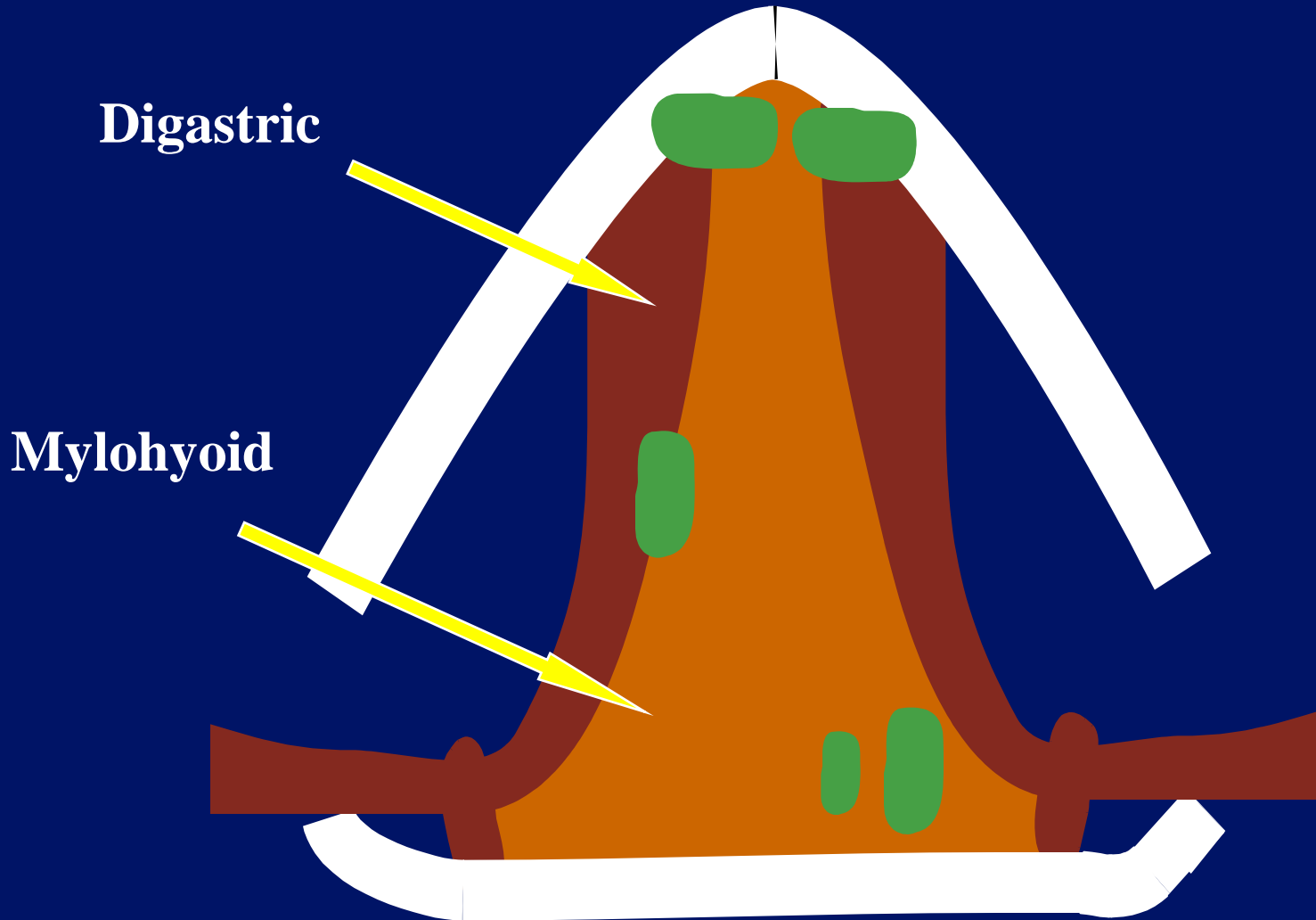
Malignant lymph nodes.



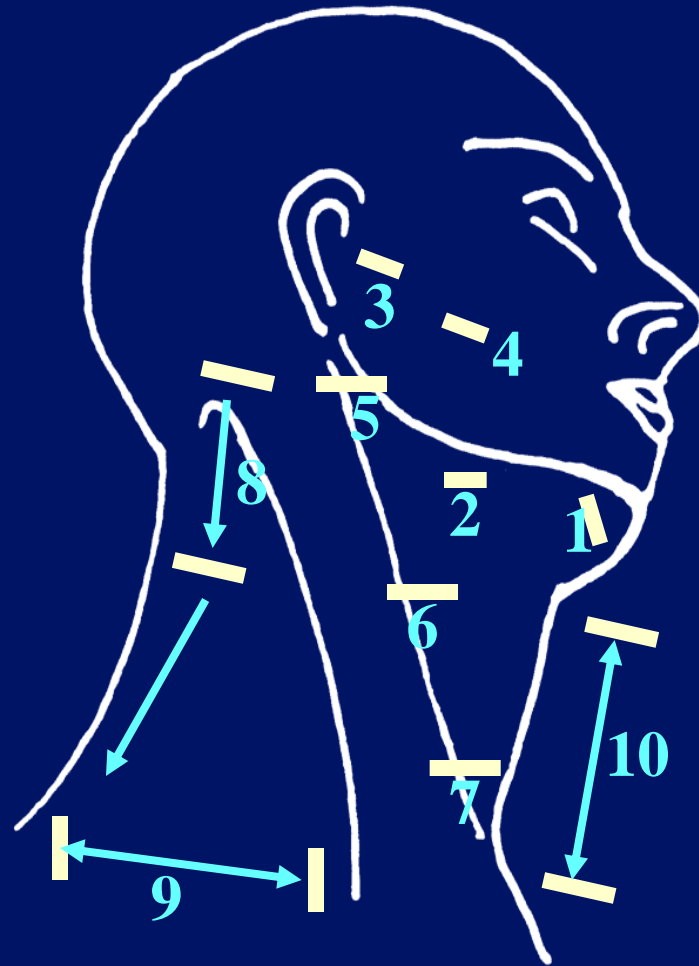
Lymph Node Examination



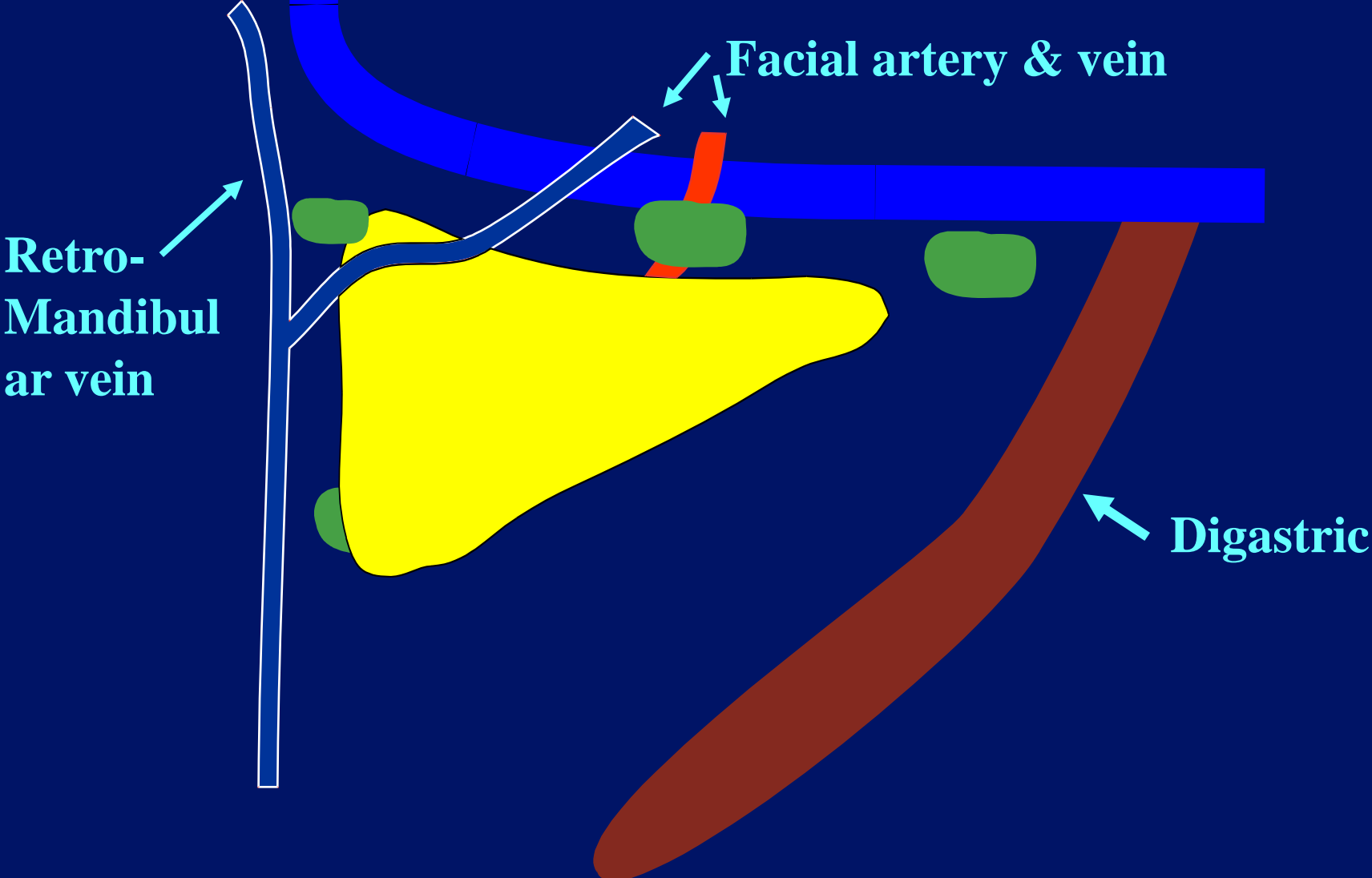
Submental



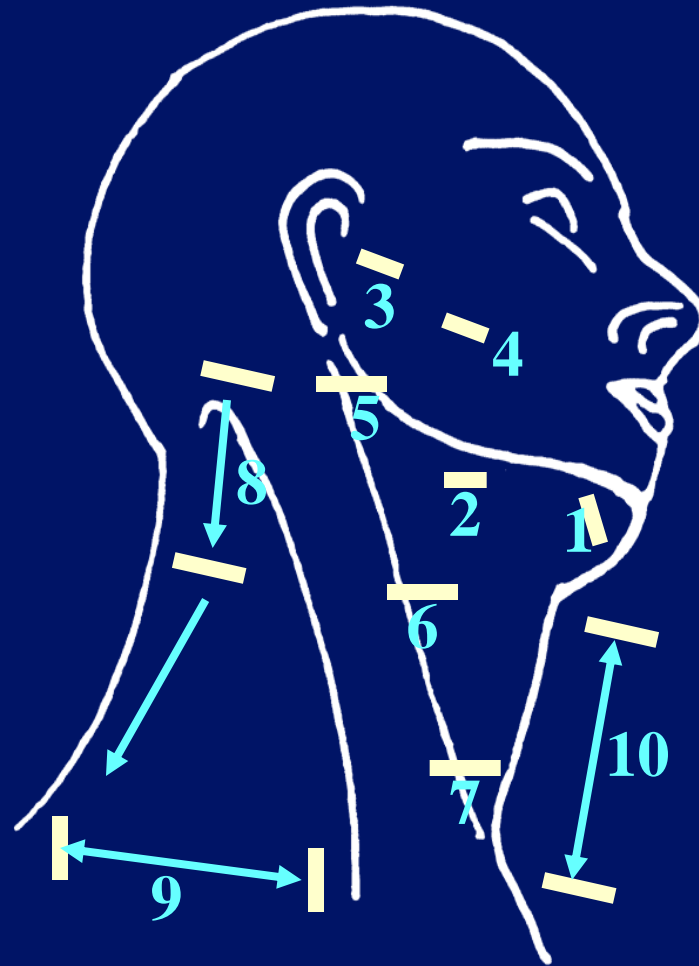
Lymph Node Examination




Submandibular




Lymph Node Examination






**Superficial
Pre-auricular**



**Sub fascial
Pre-auricular**

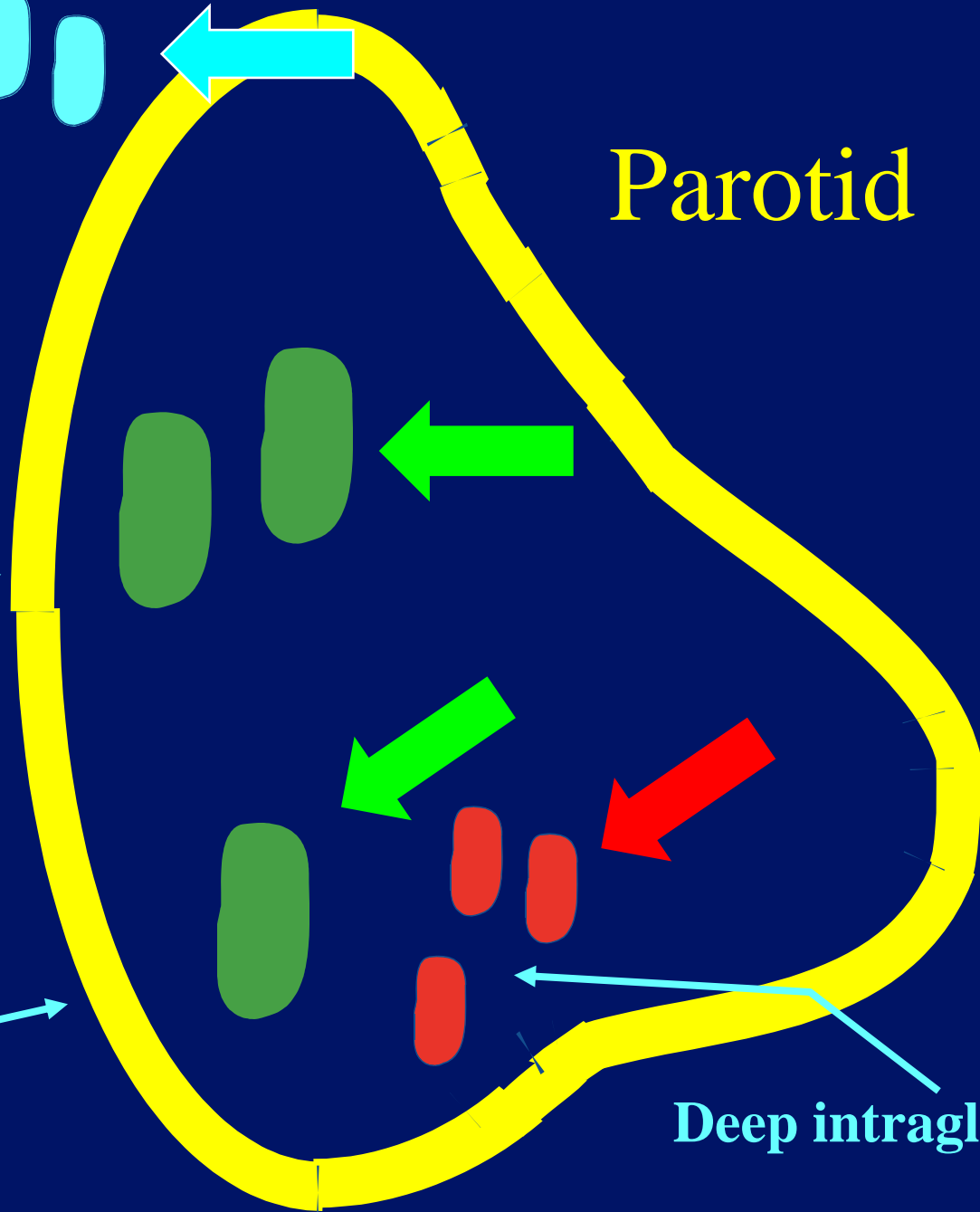


**Sub fascial
Infra-auricular**

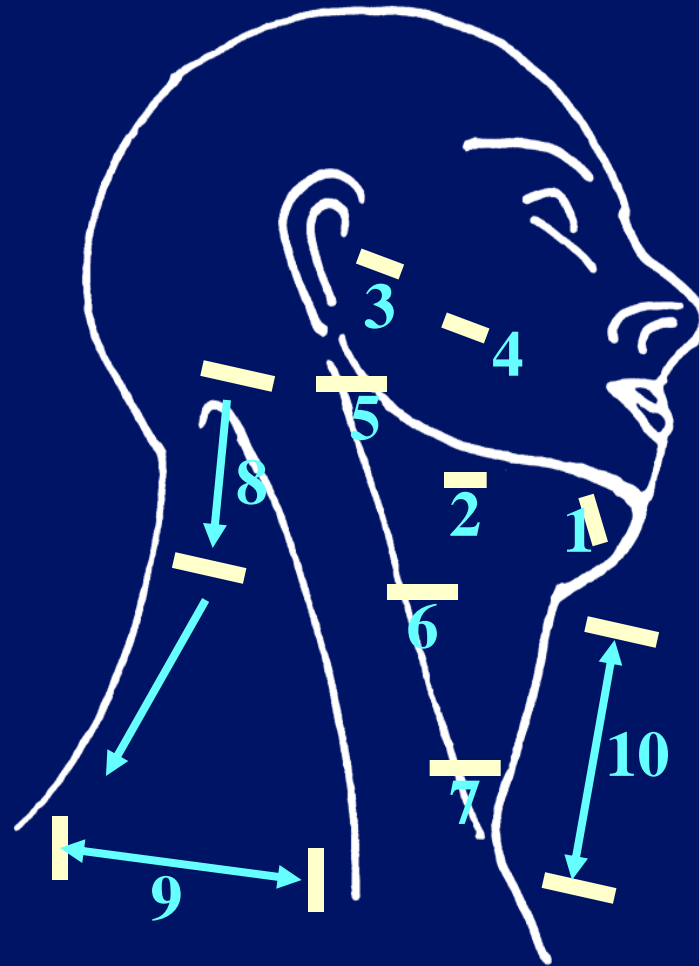


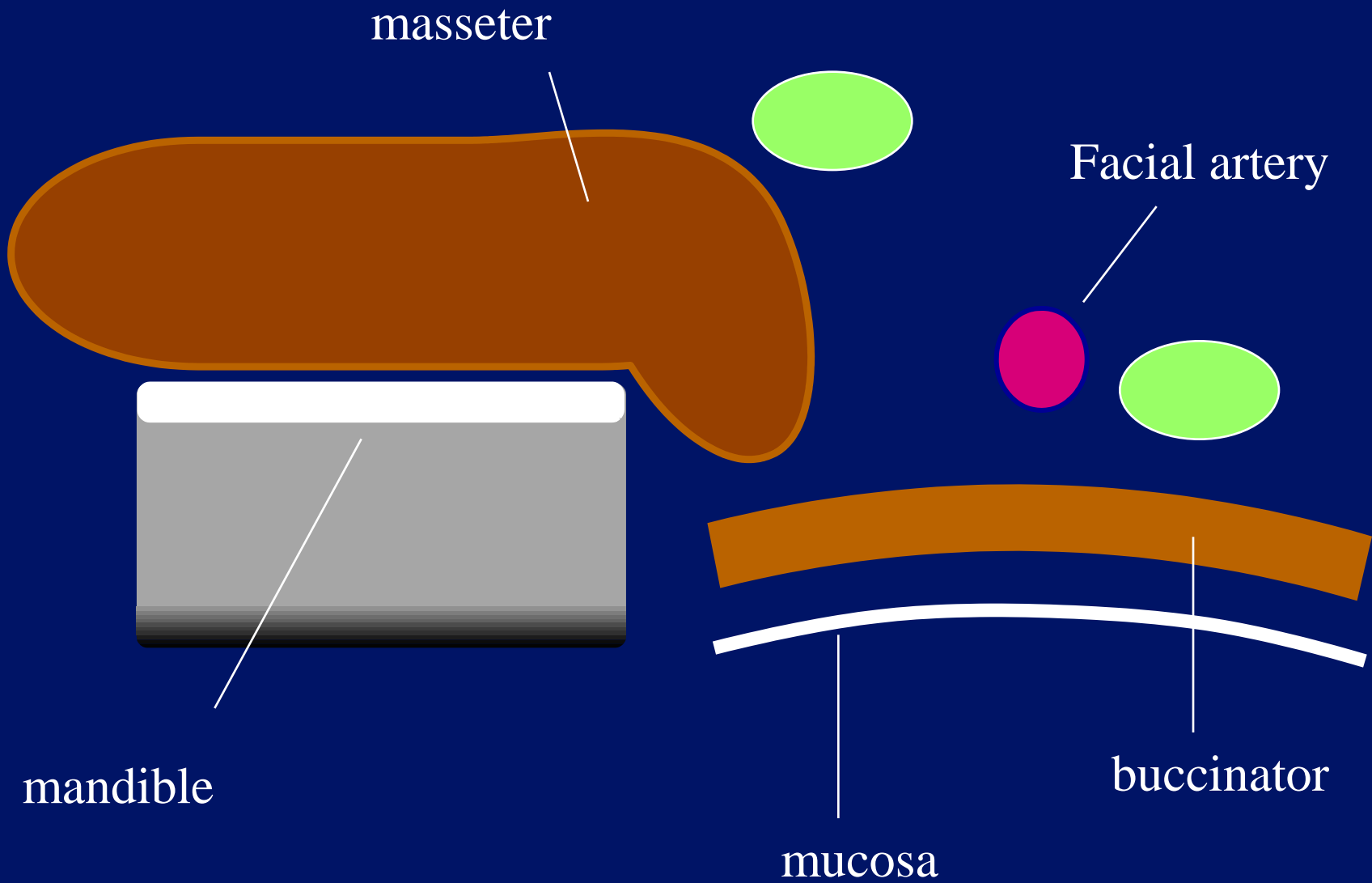
Deep intraglandular

Parotid

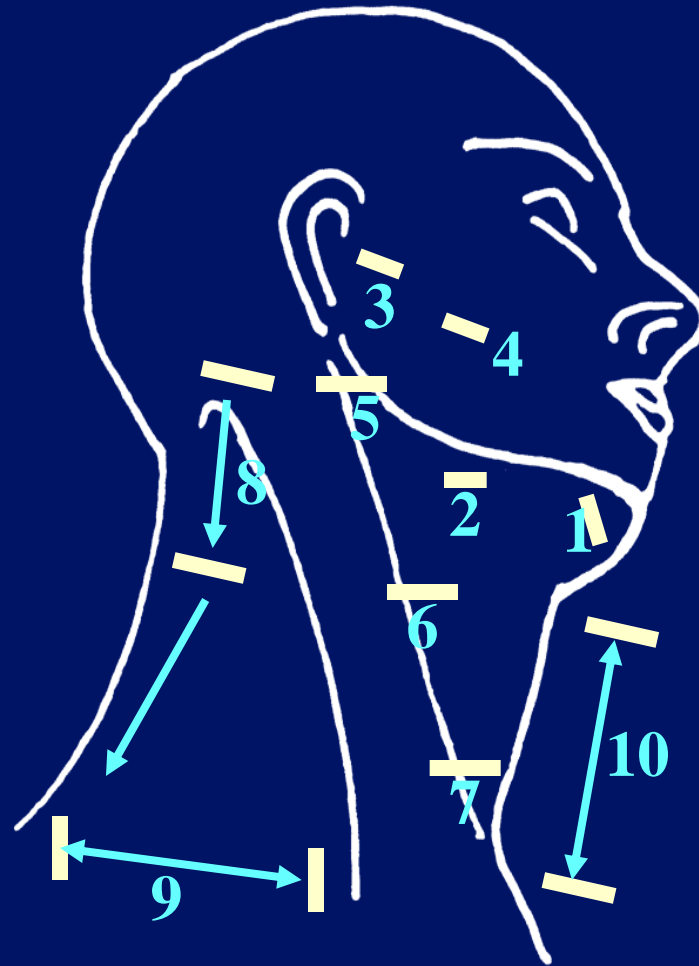


Lymph Node Examination

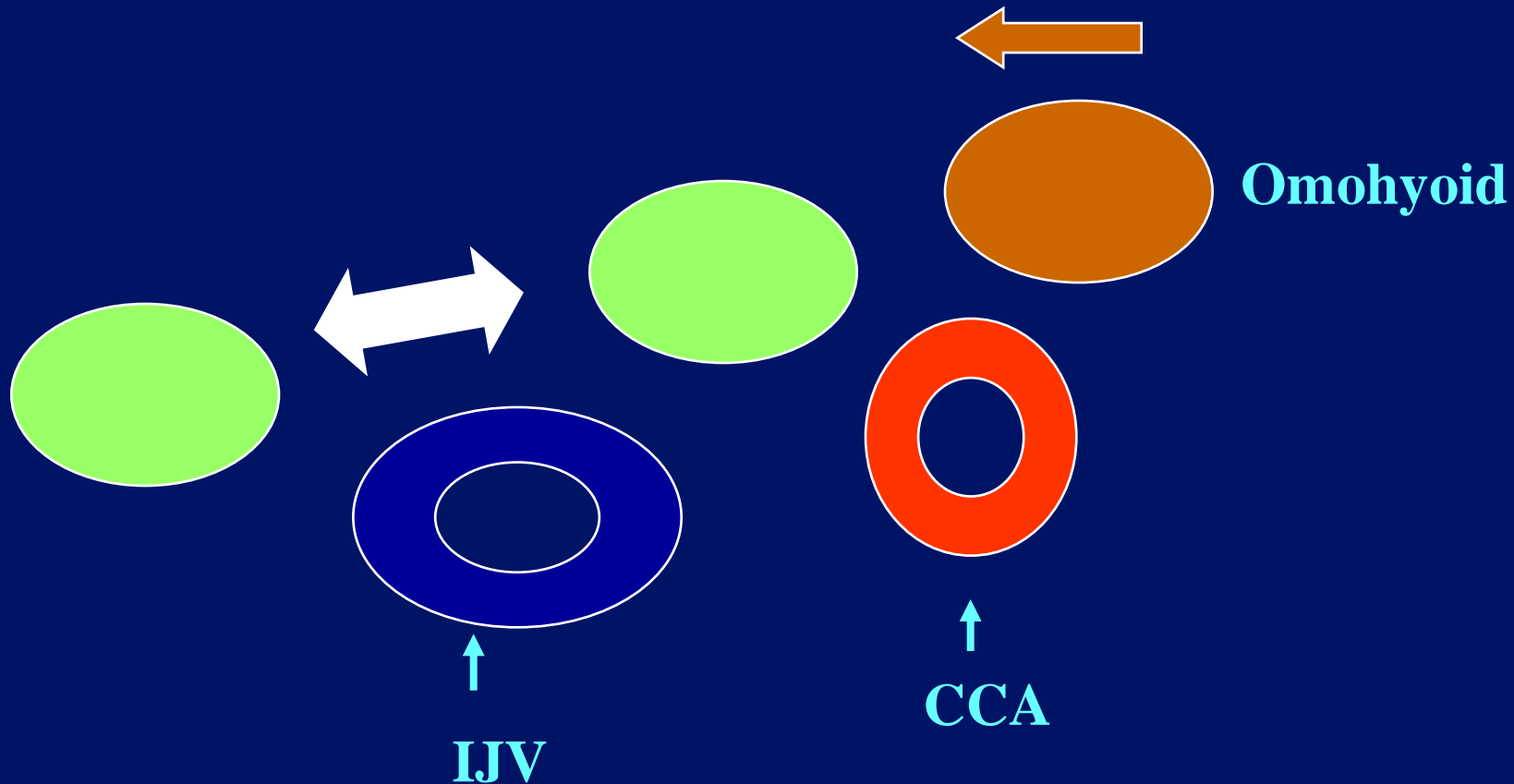




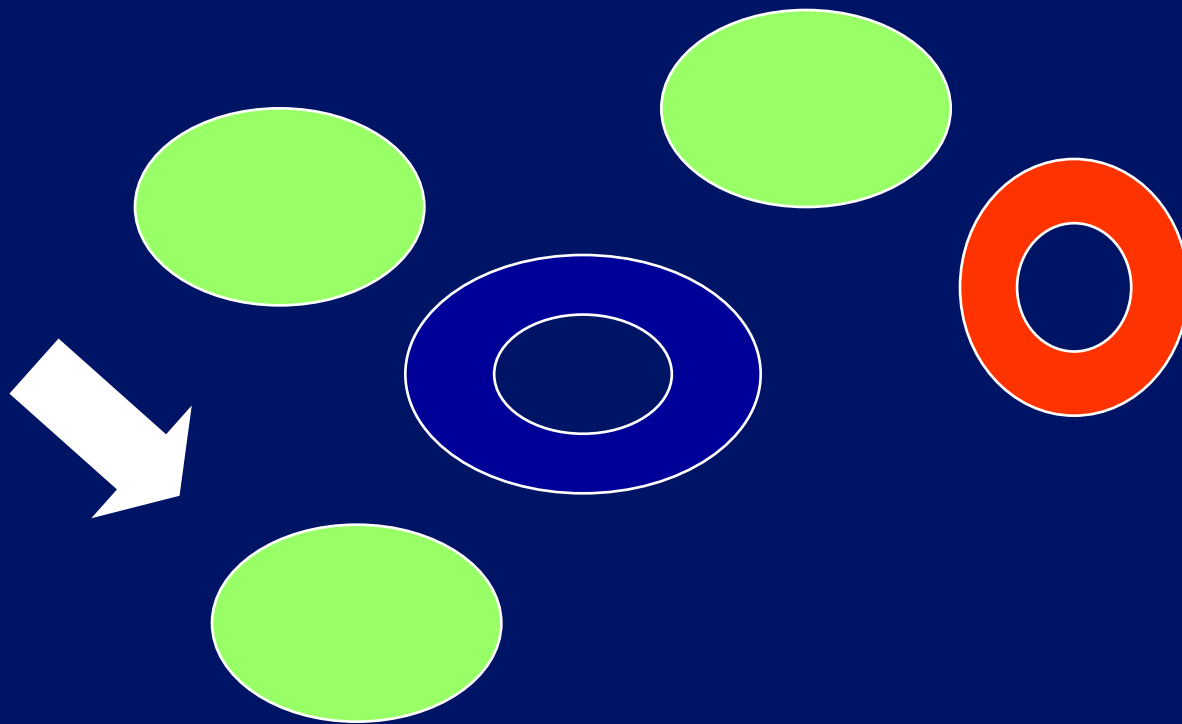
Lymph Node Examination



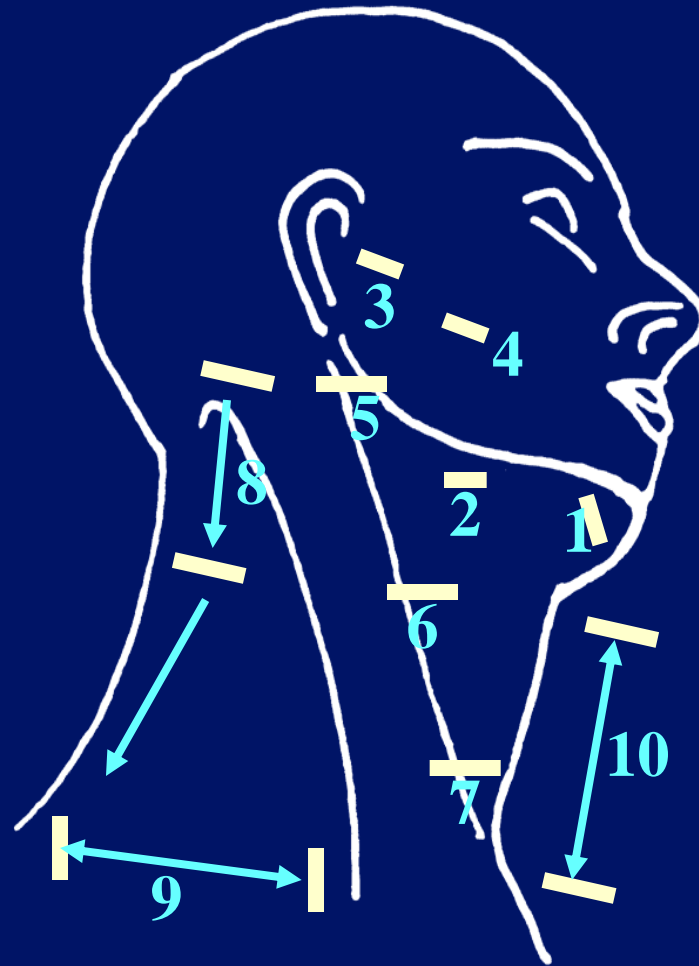
Deep Cervical Chain



Deep Cervical Chain



Lymph Node Examination



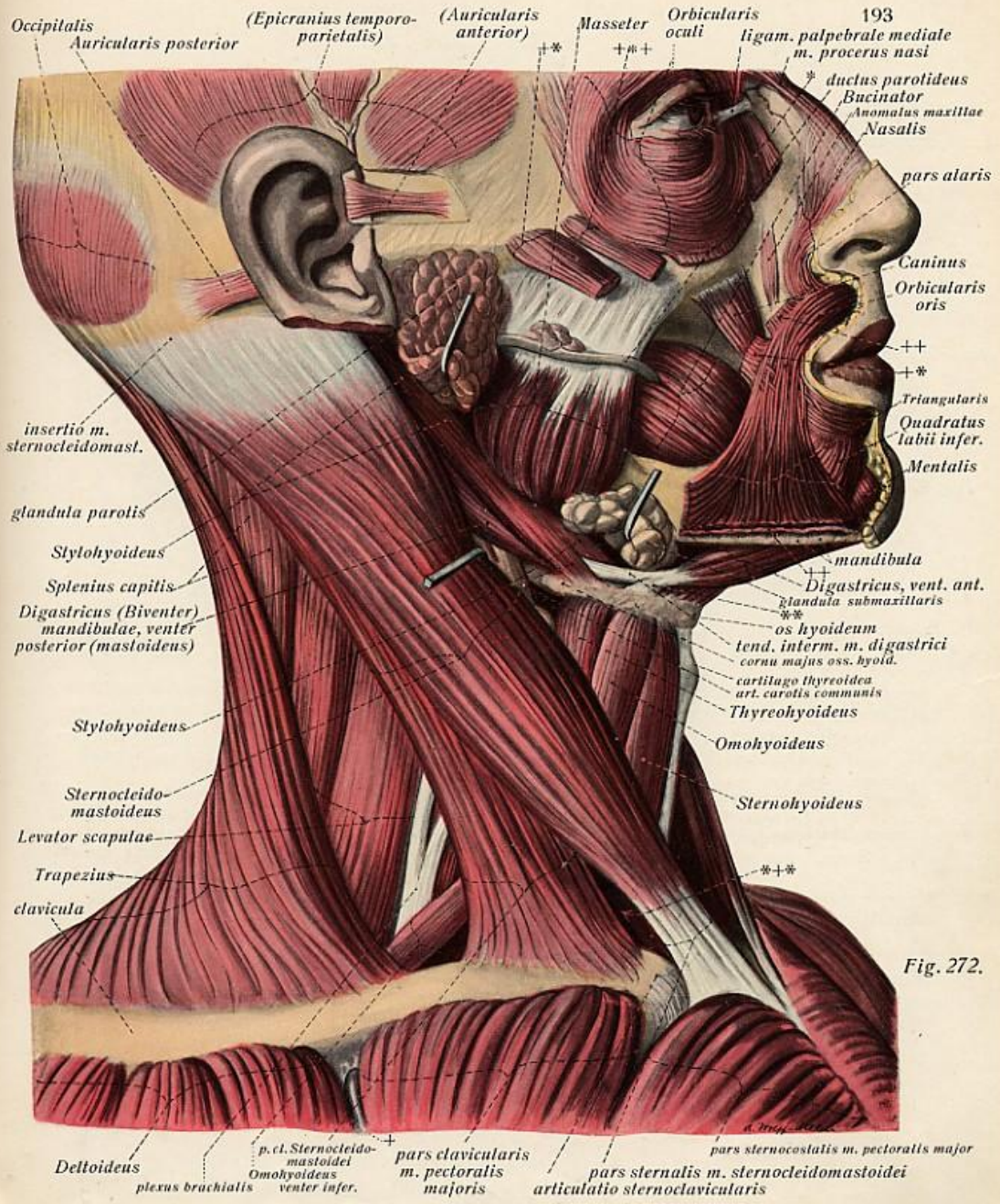


Fig. 272.

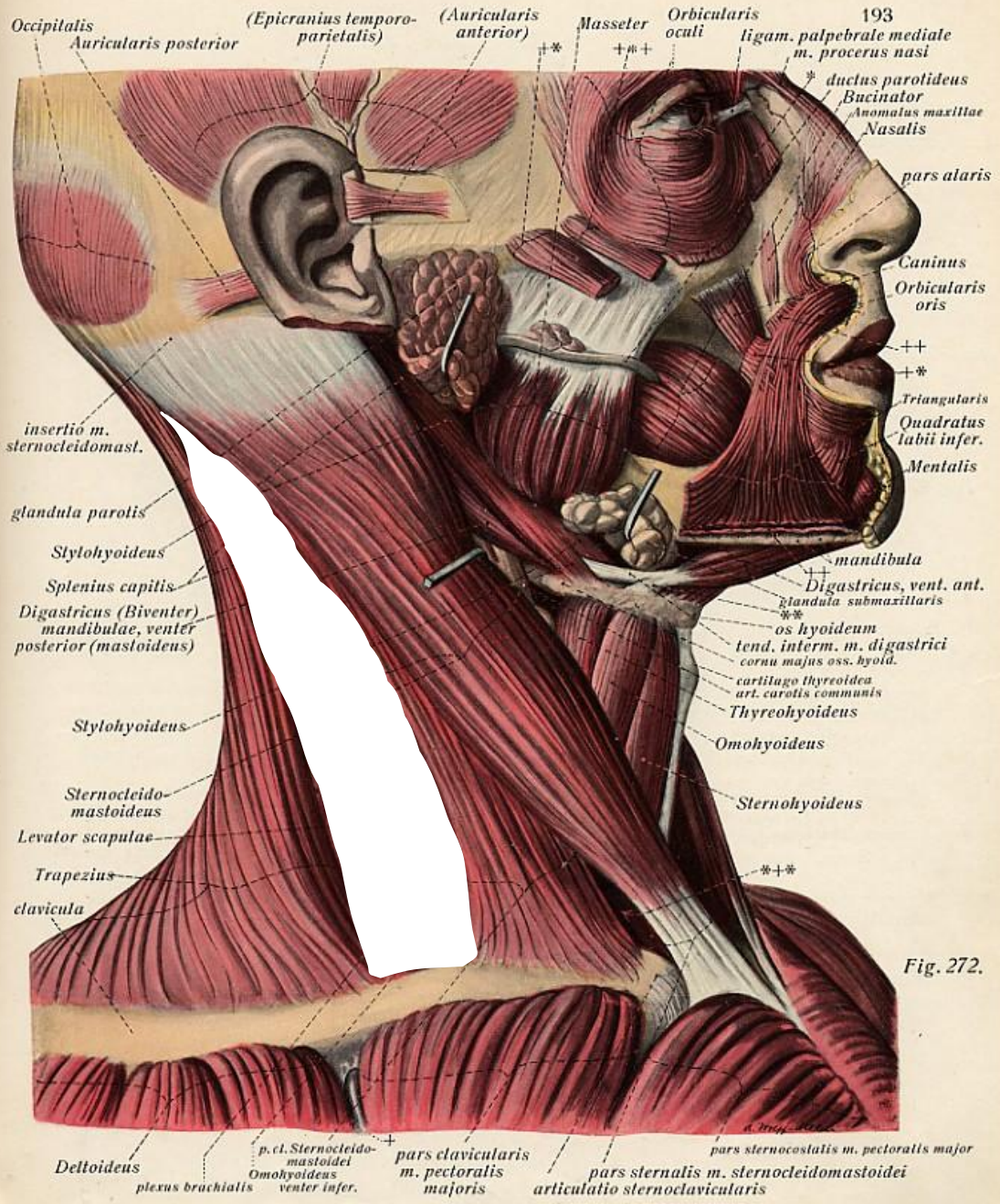
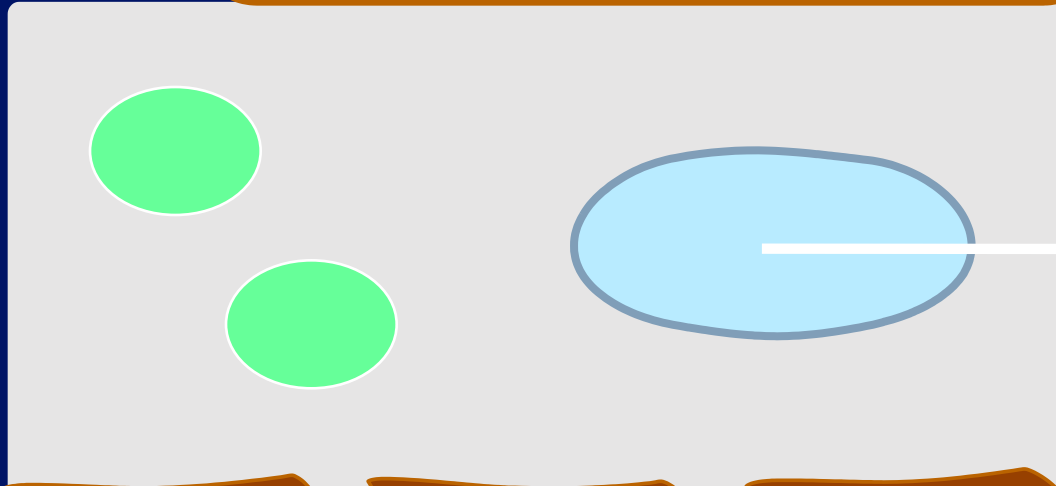

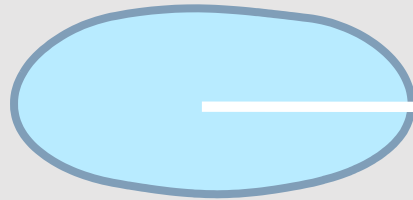


Fig. 272.

Sternomastoid




I.J.V



Scalenus Posterior




Scalenus Medius

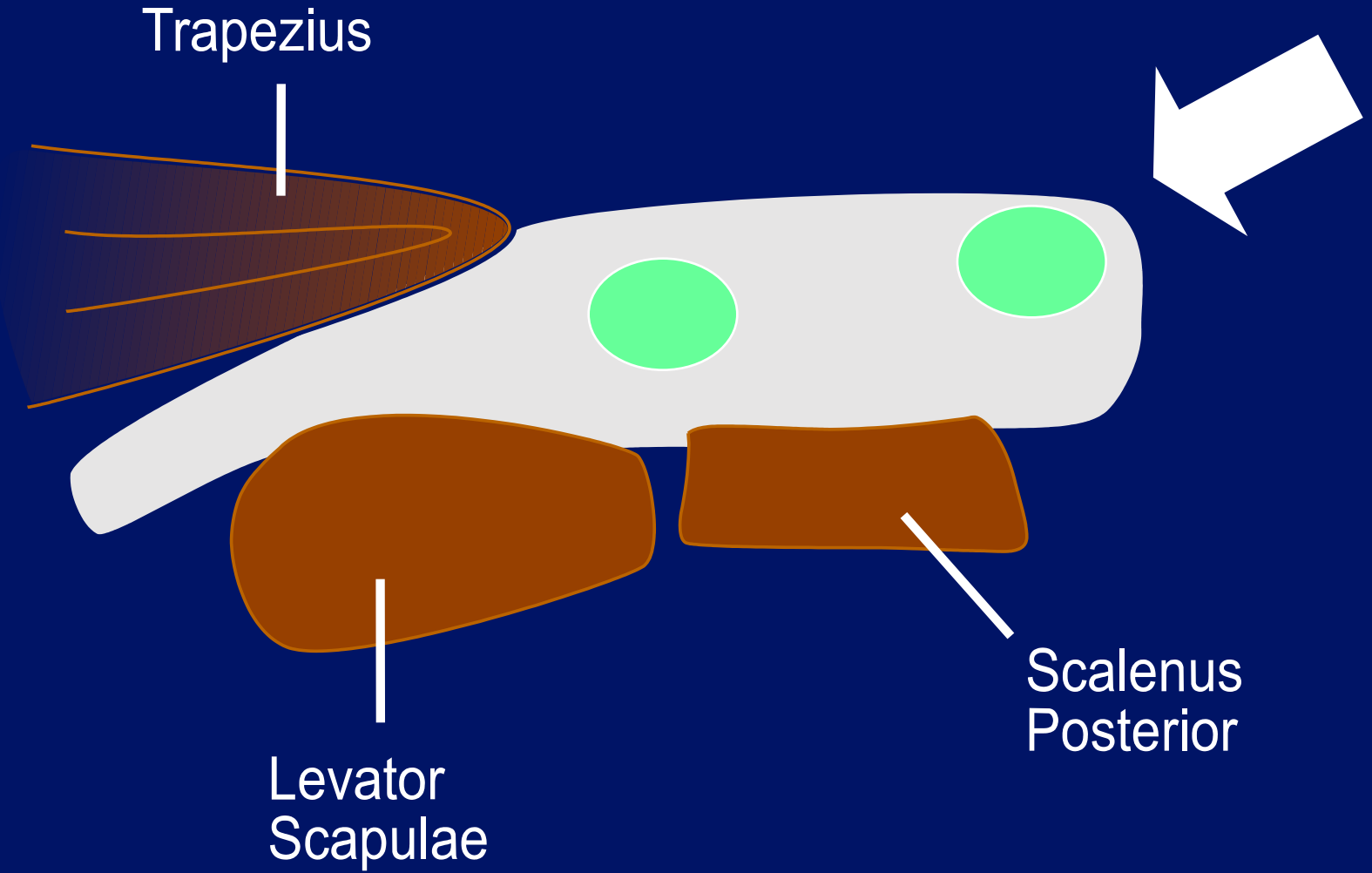


Brachial Plexus

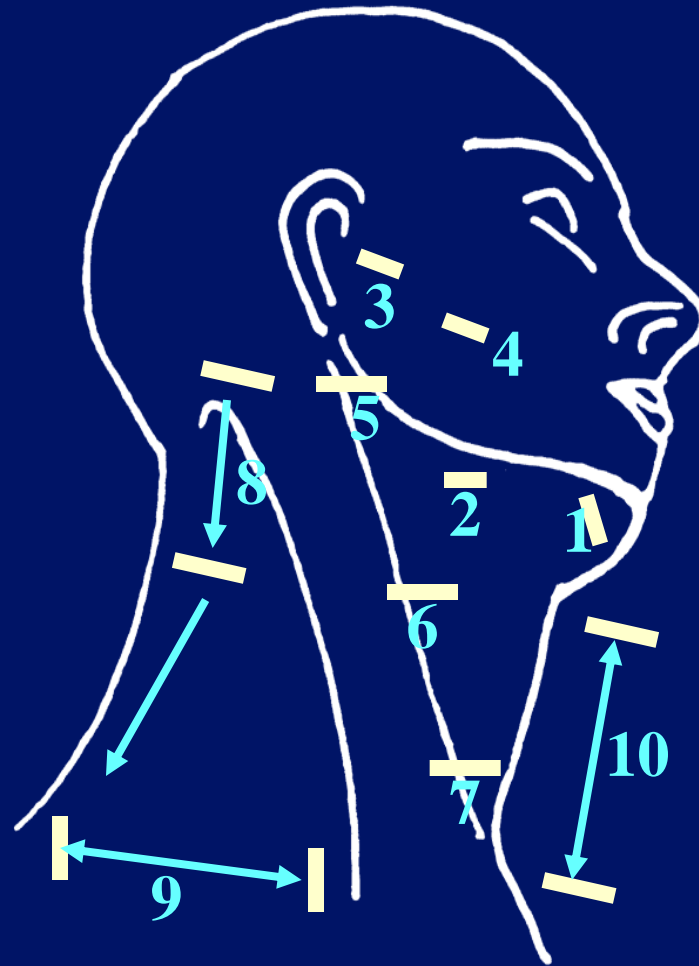


Scalenus Anterior

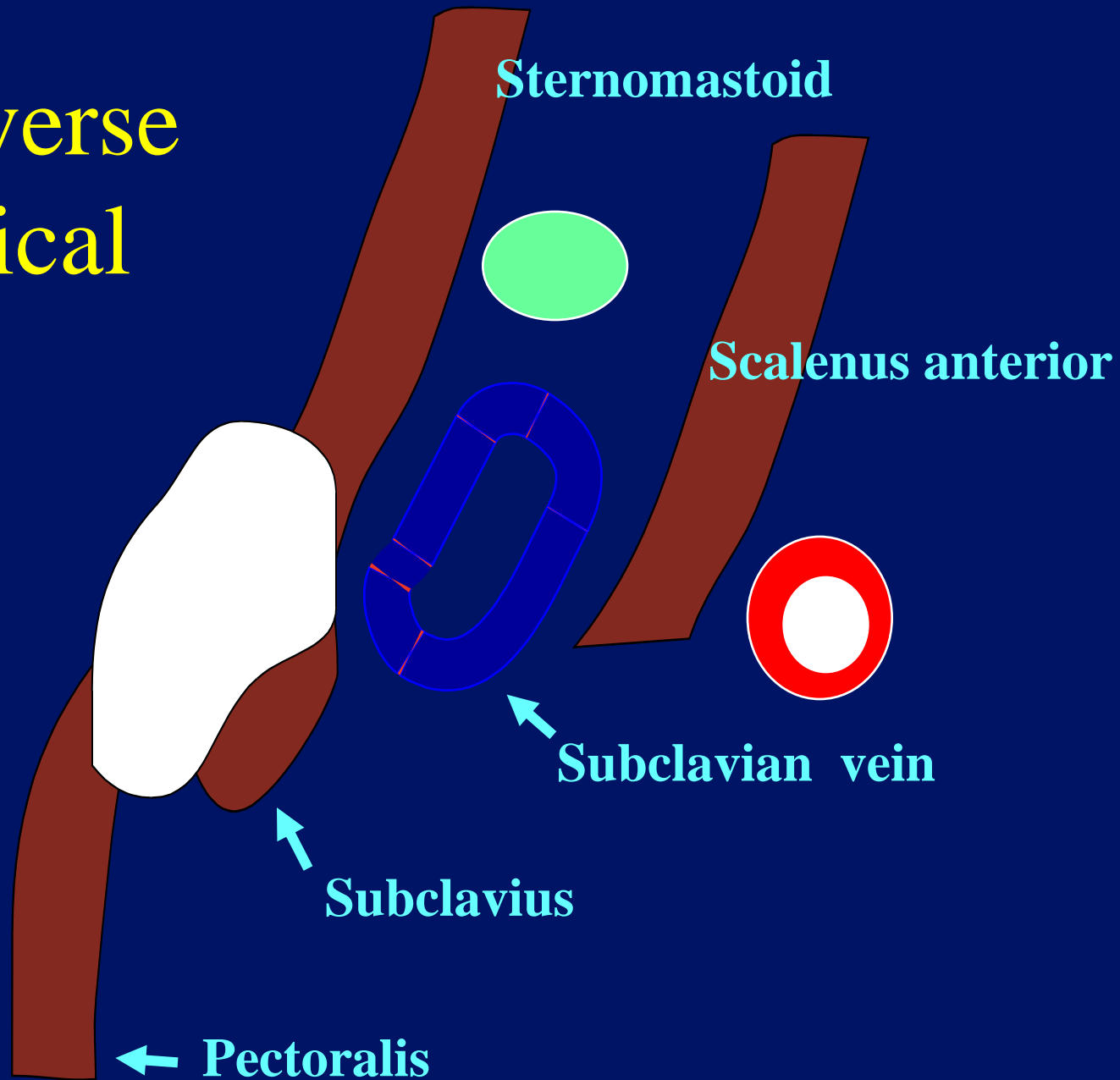




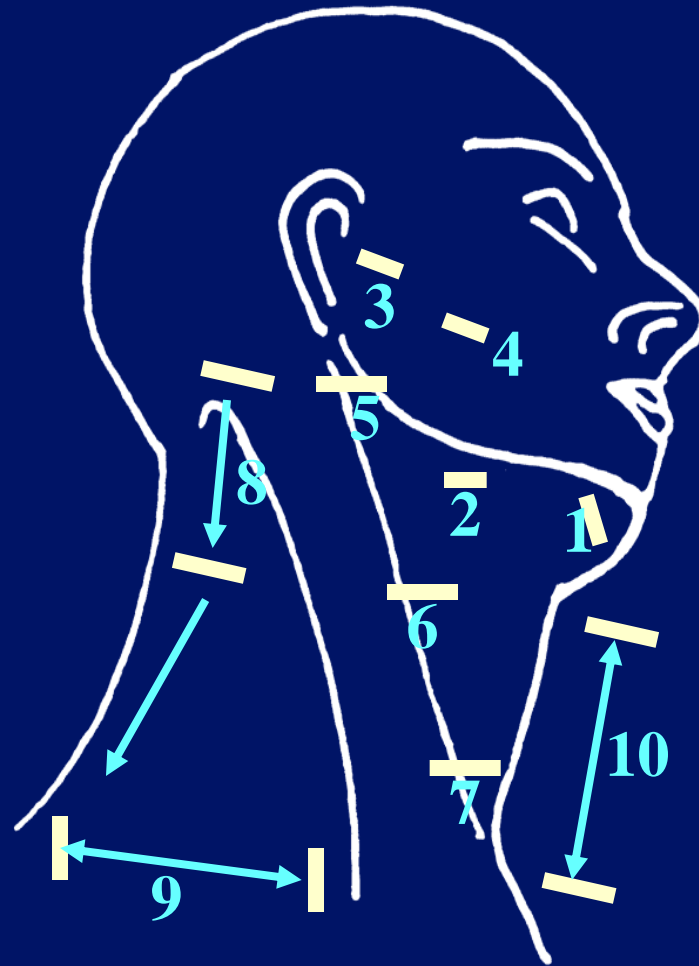
Lymph Node Examination



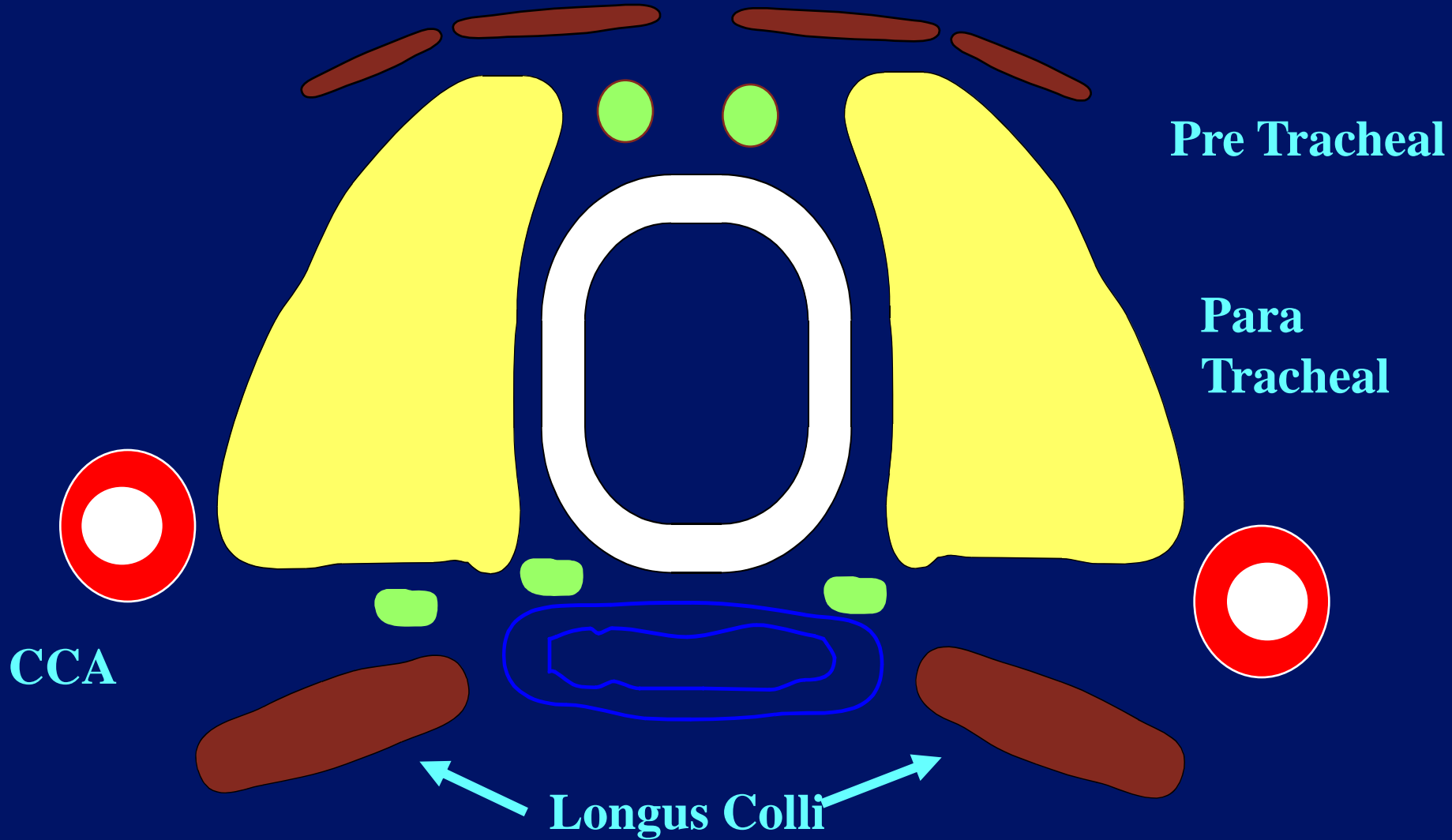
Transverse Cervical



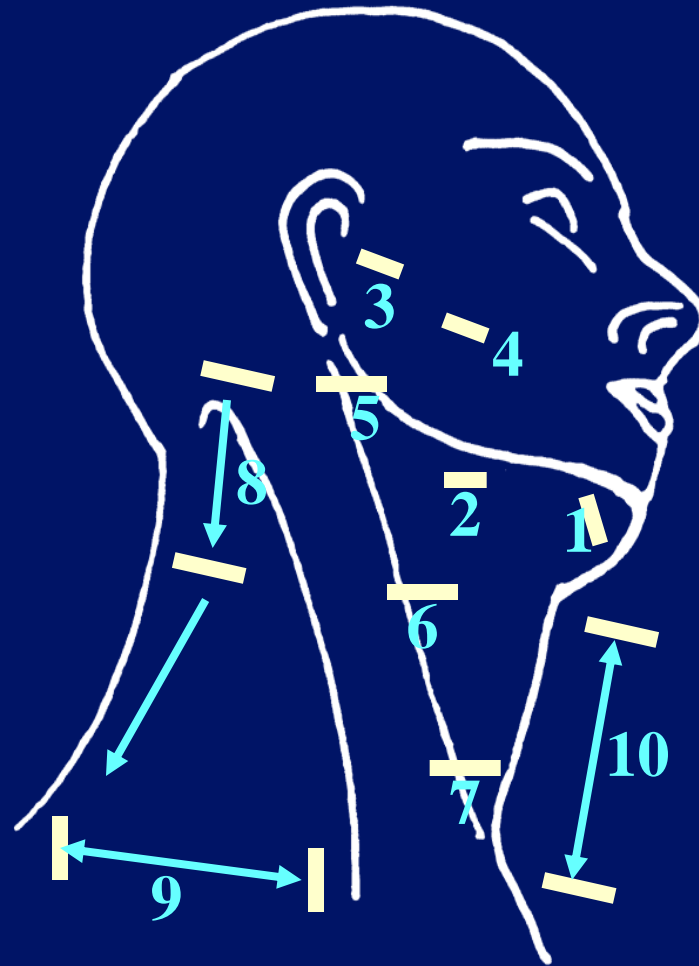
Lymph Node Examination



Anterior Cervical




Lymph Node Examination




Pseudo-cystic?


- Lymphoma.
- Pleomorphic adenoma.
- Nerve sheath tumour.
- Parathyroid adenoma.



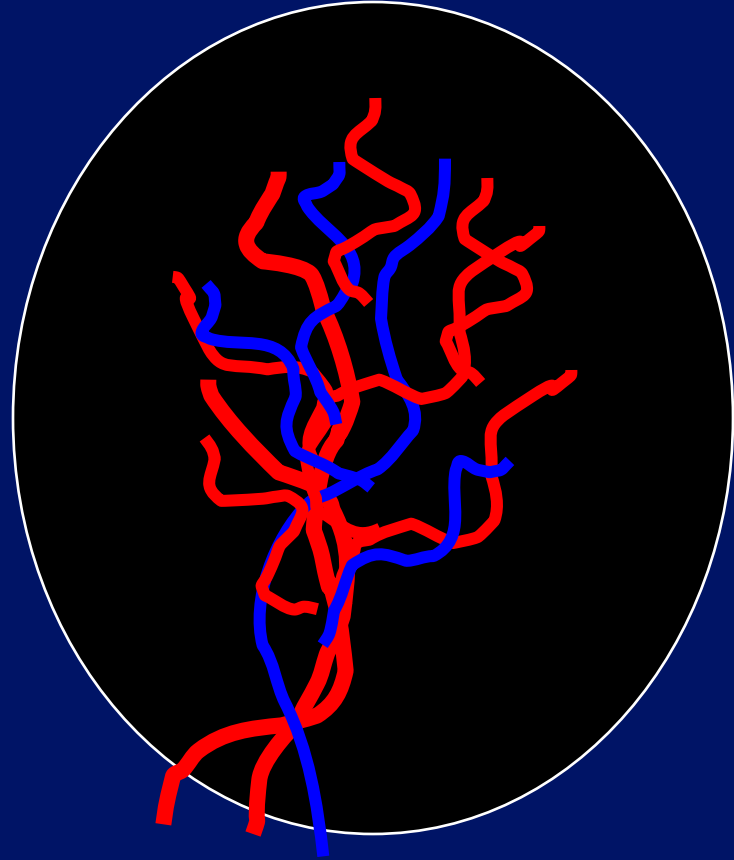
? Lymphoma



? Lymphoma



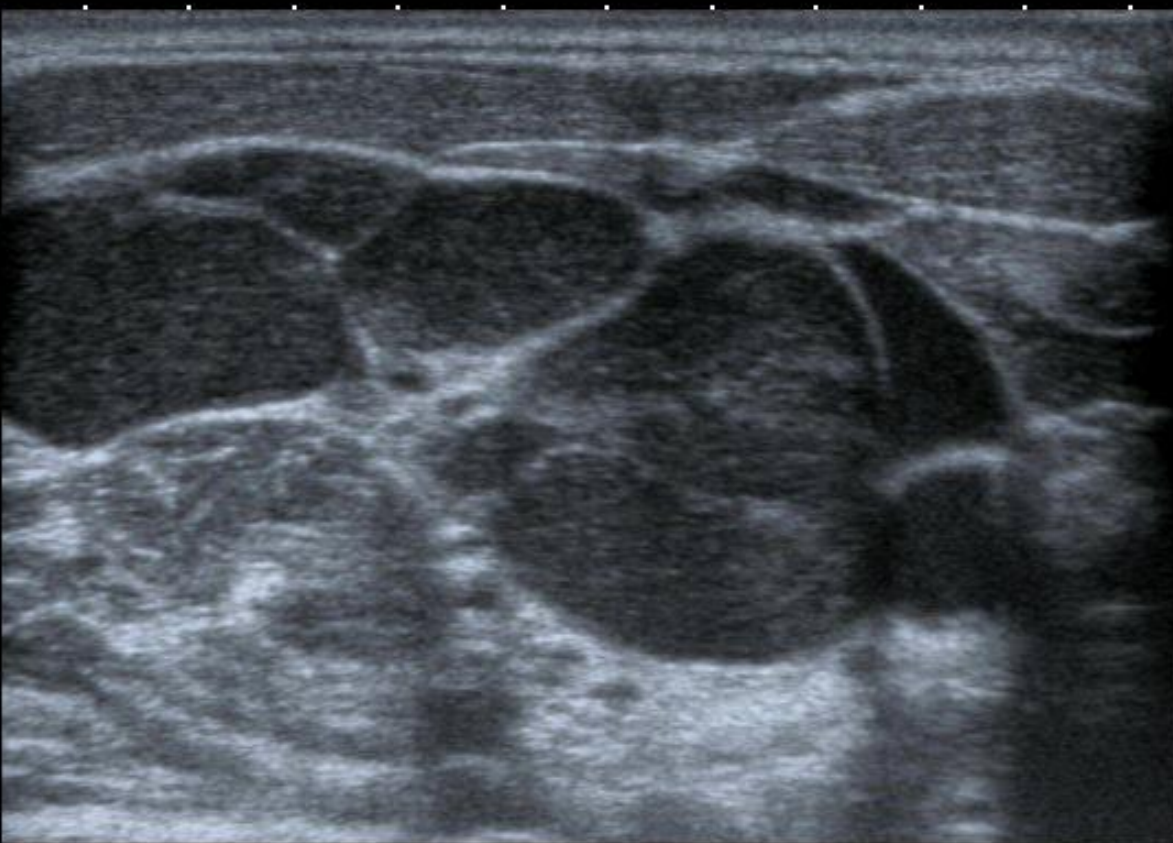
? Lymphoma




T
0
1
2
3
4

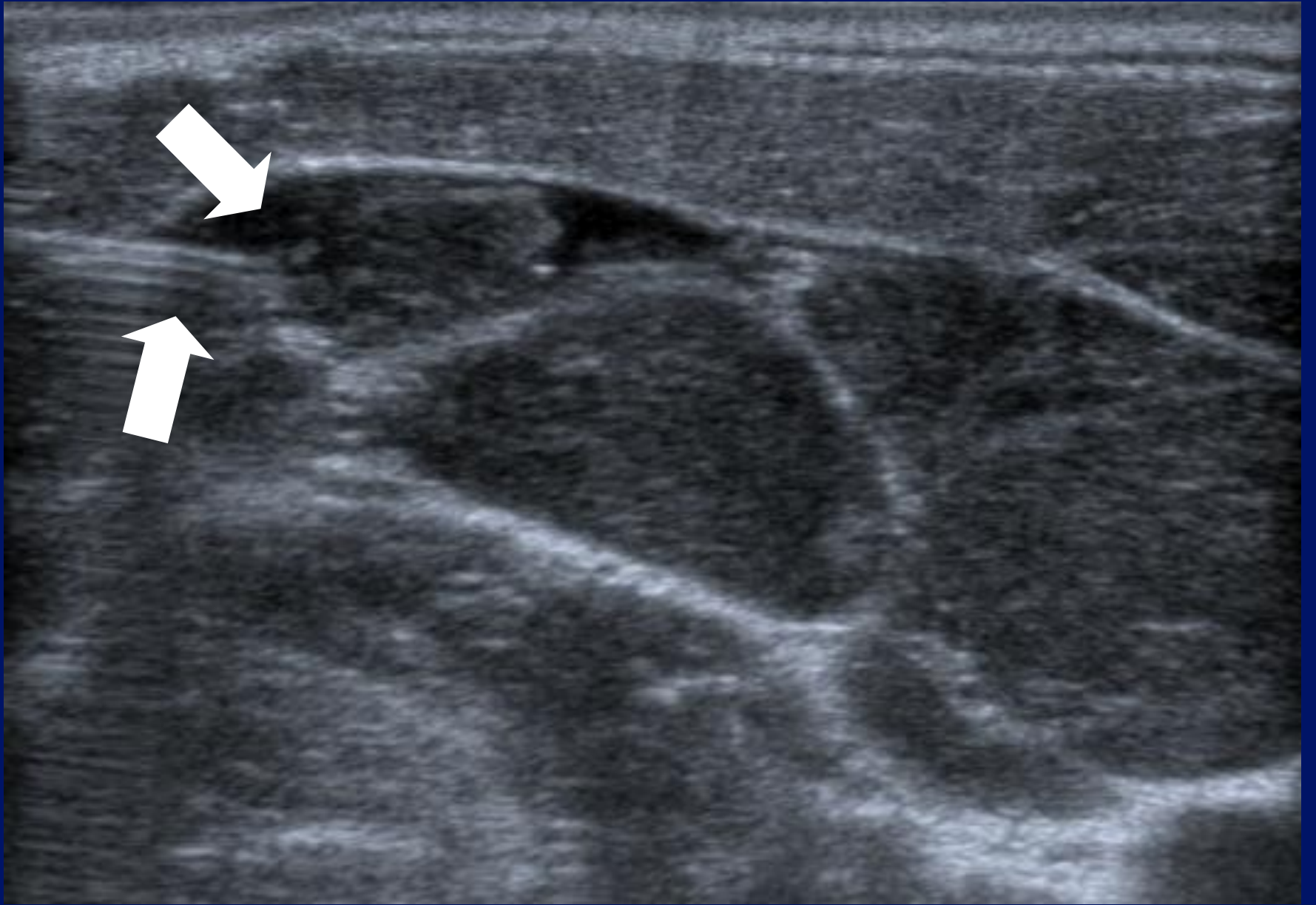
12L5
T9.0

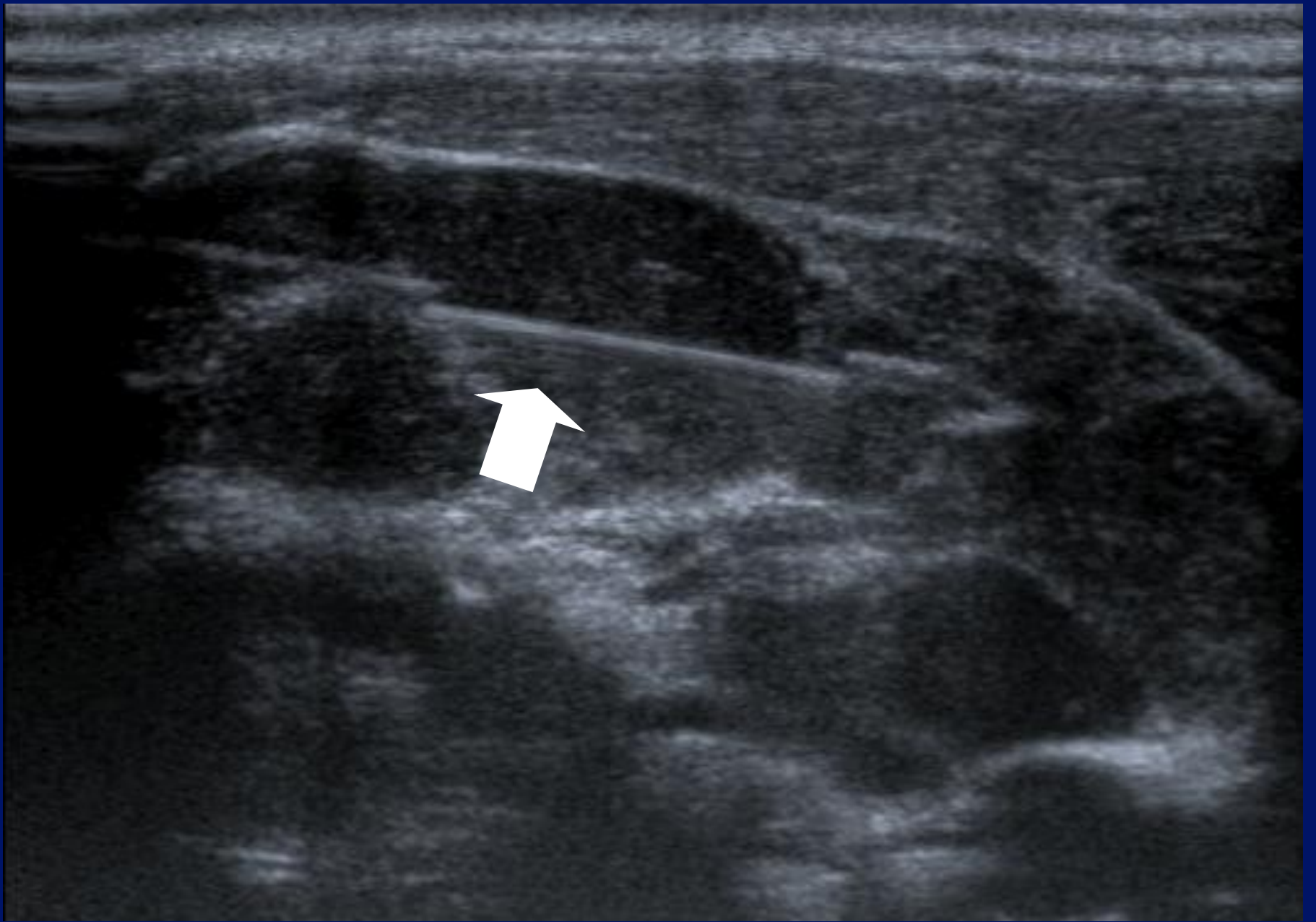
33 fps

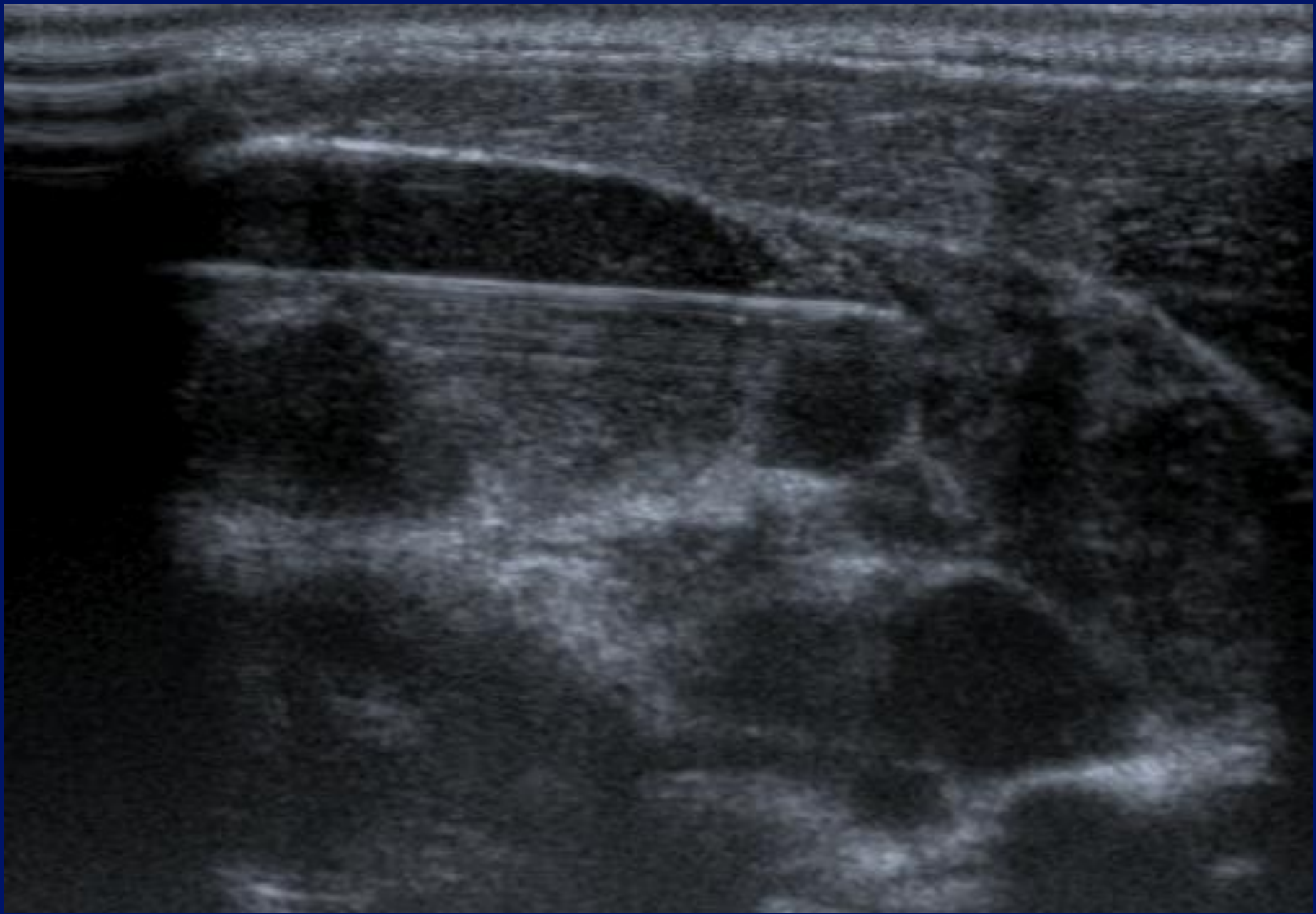



MI:1.6
2DG
80
DR
70






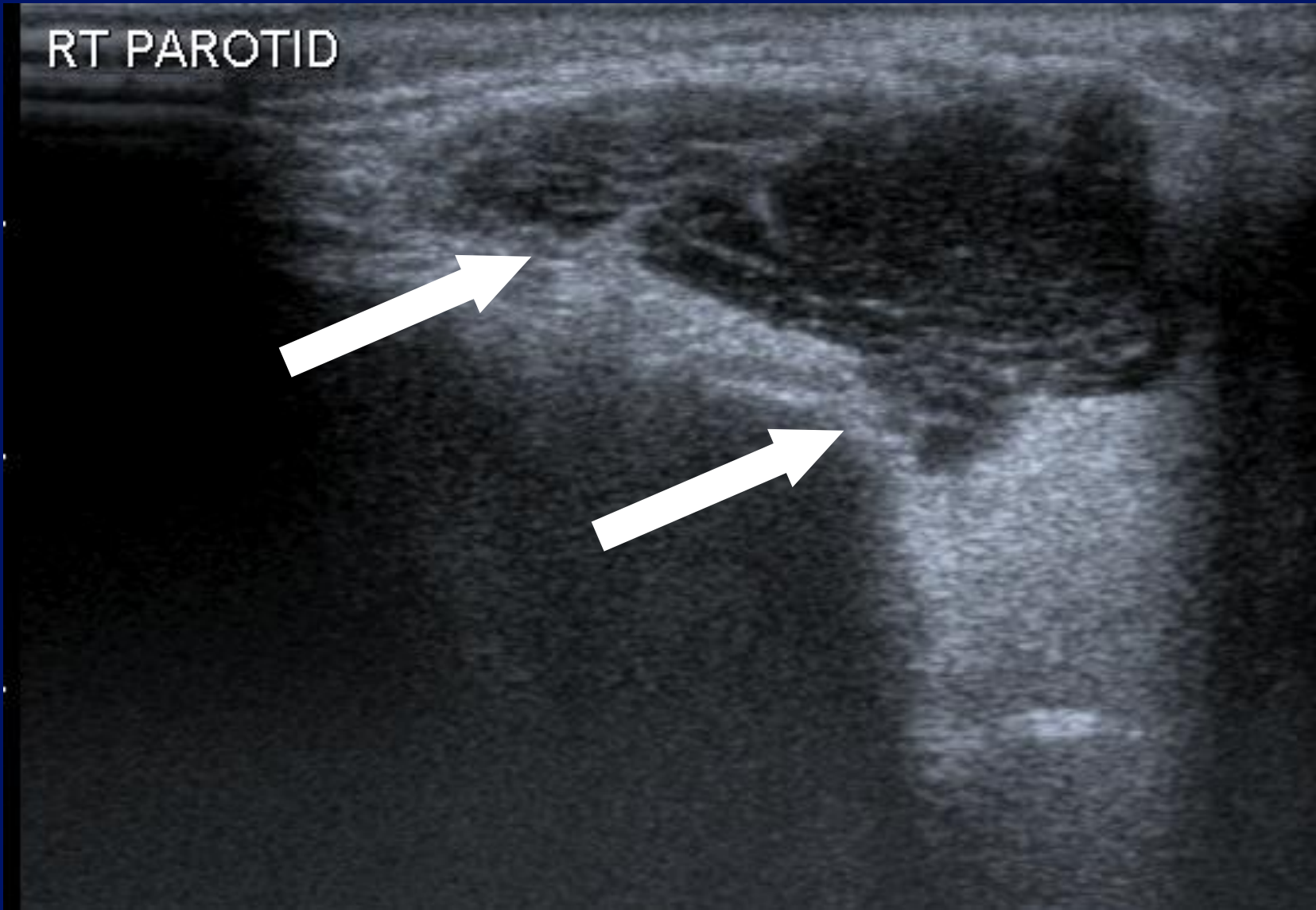


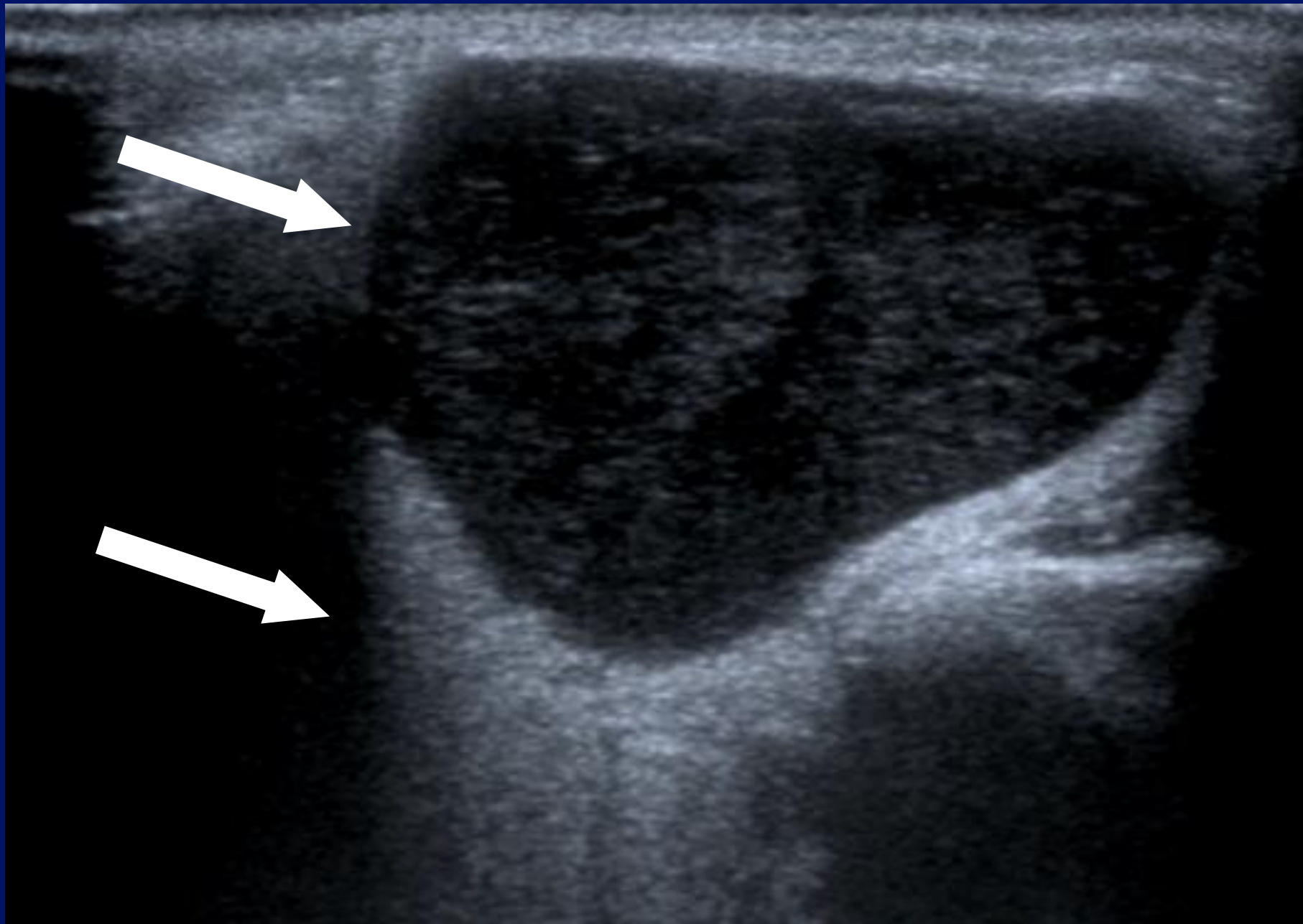

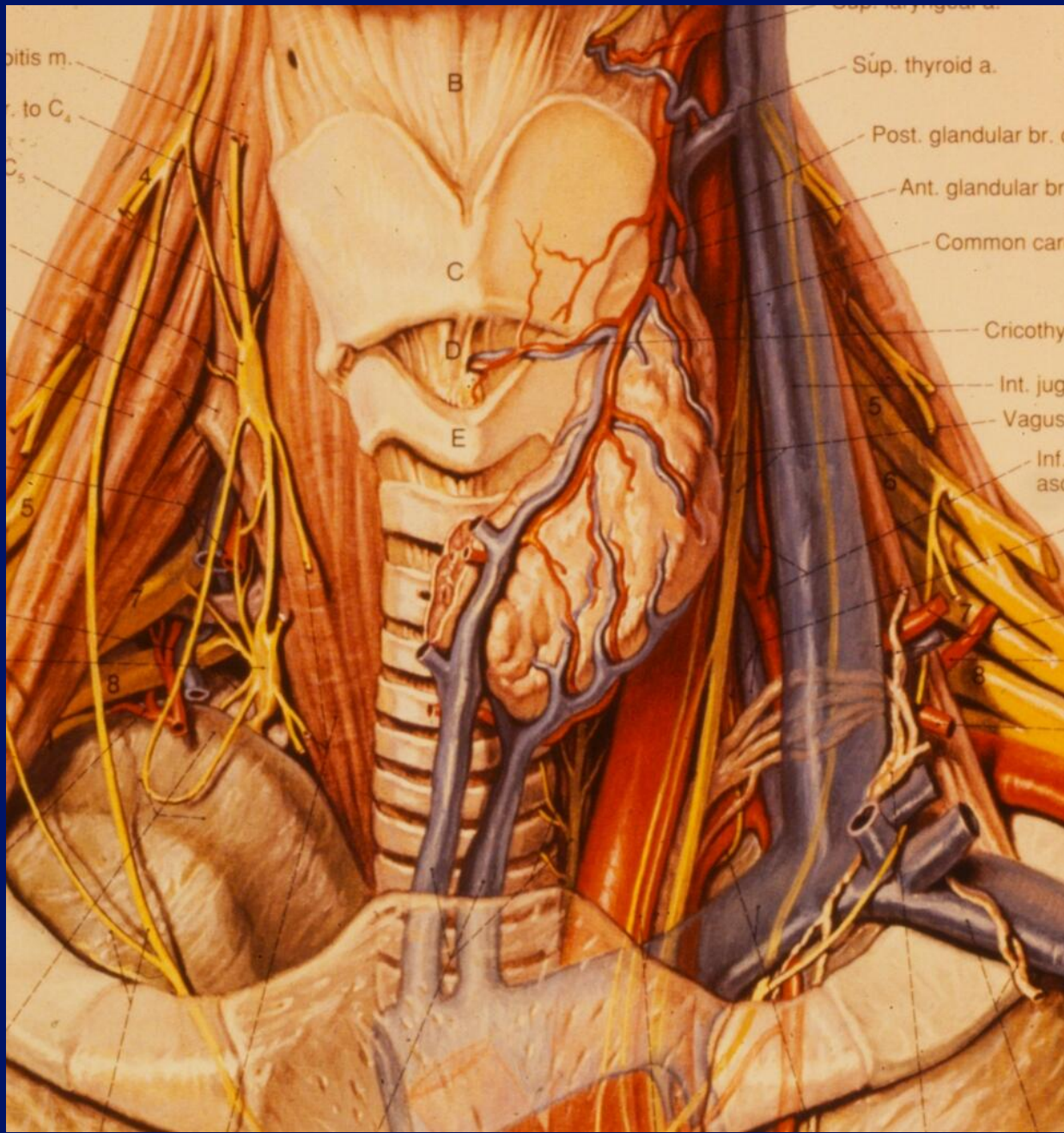




RT PAROTID







bitis m.
r. to C₄
C₅

B

C

D

E

4

5

8

Súp. thyroid a.

Post. glandular br.

Ant. glandular br

Common car

Cricothy

Int. jug

Vagus

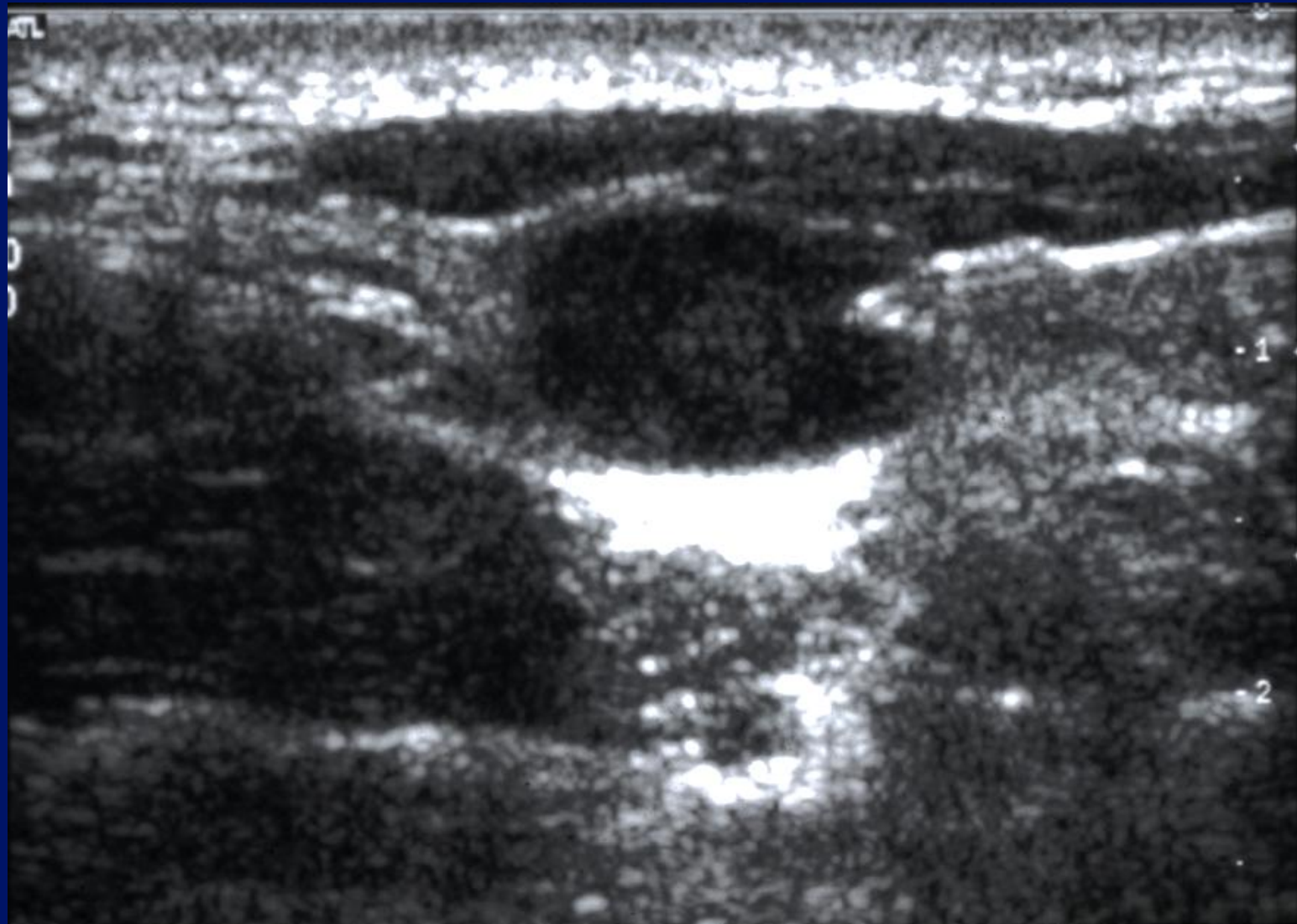
Inf. asc

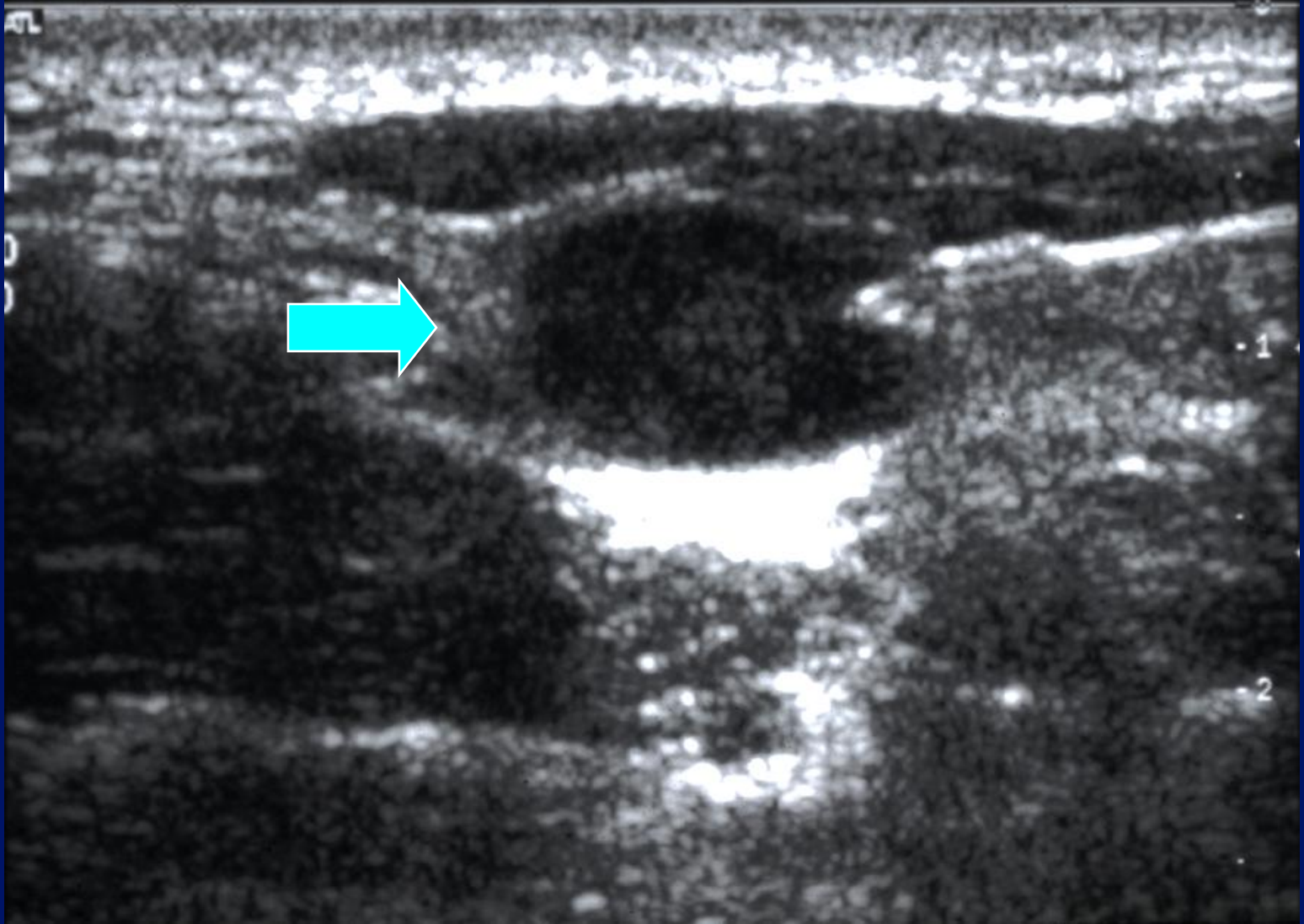
5

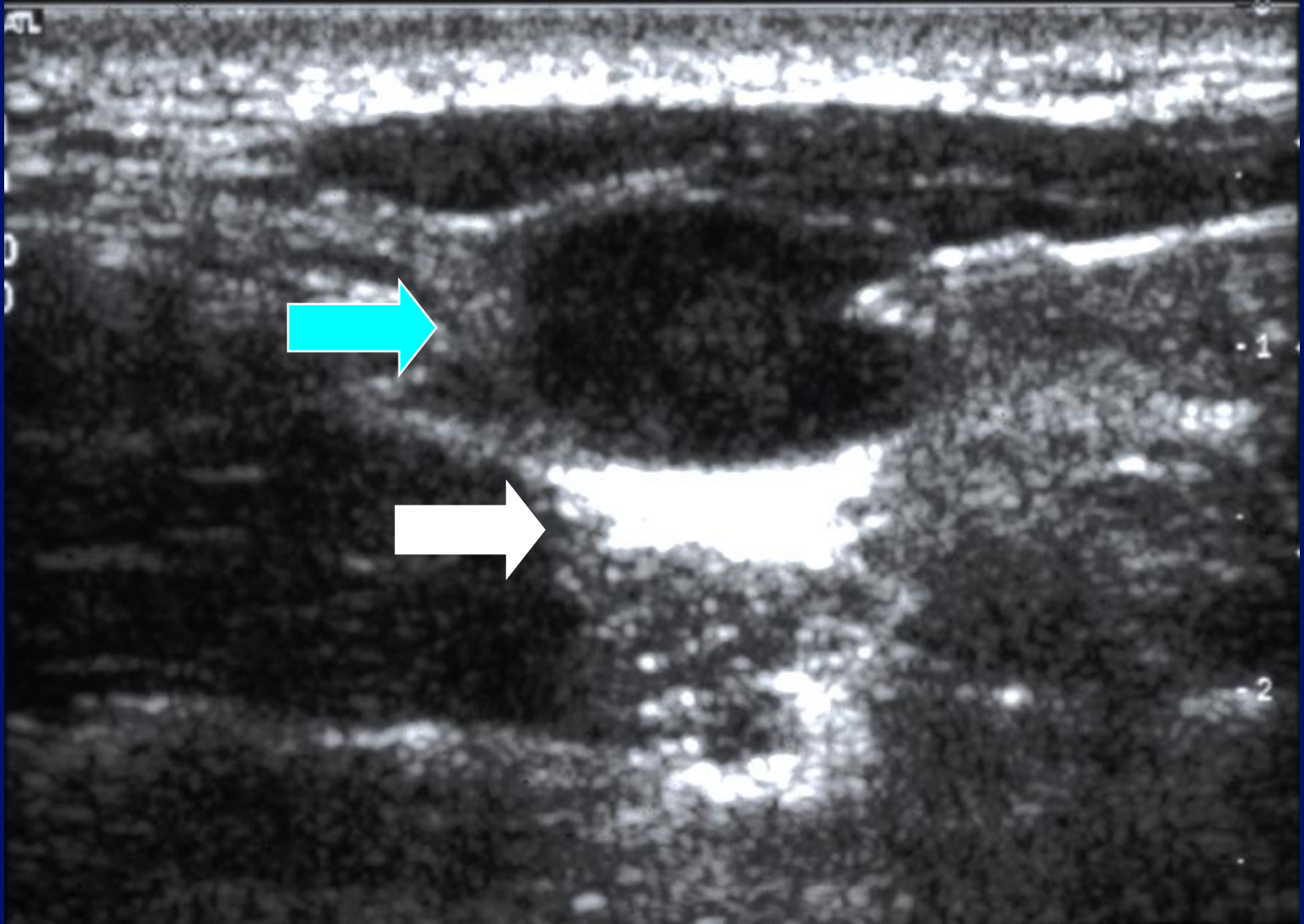
6

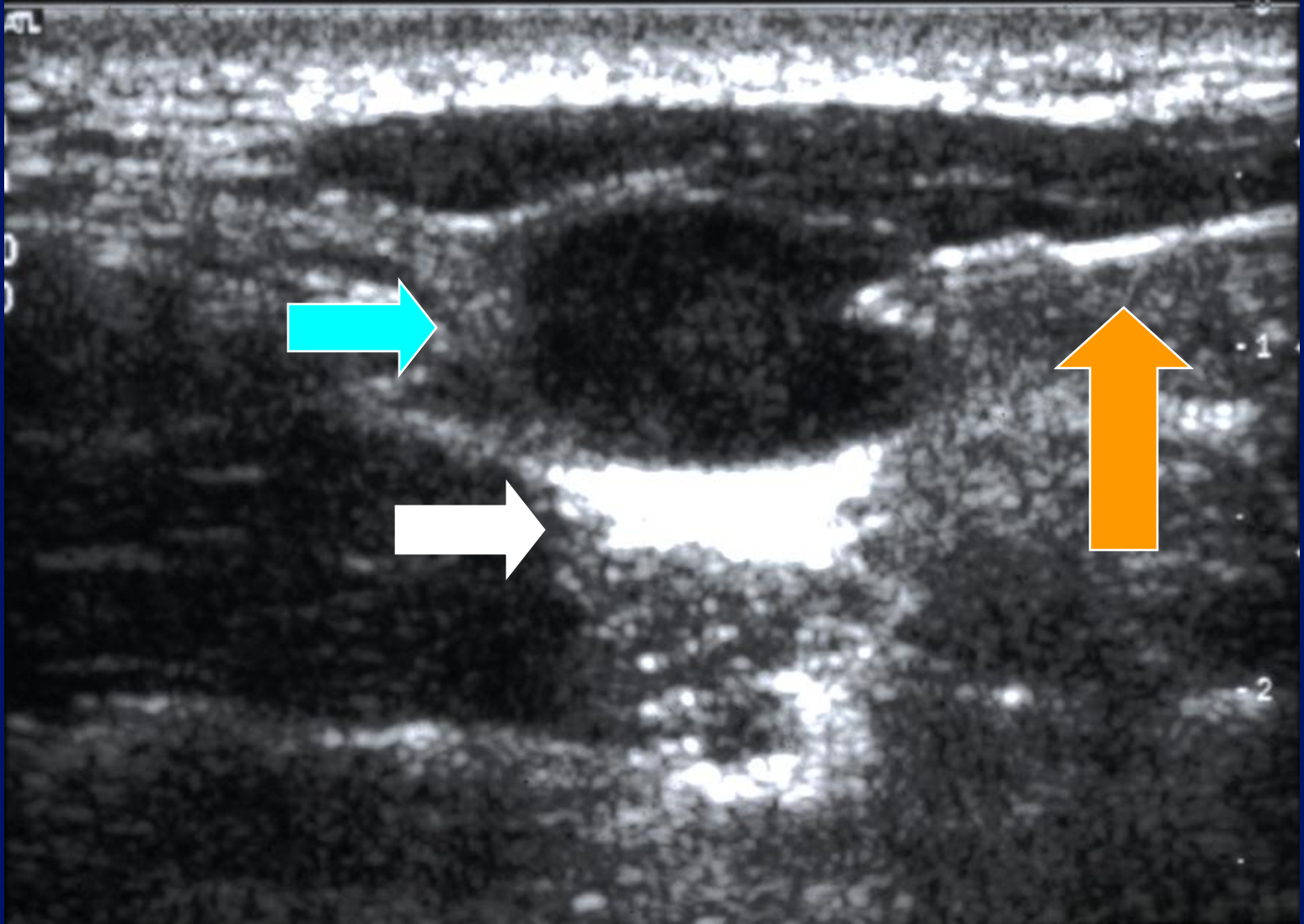
8

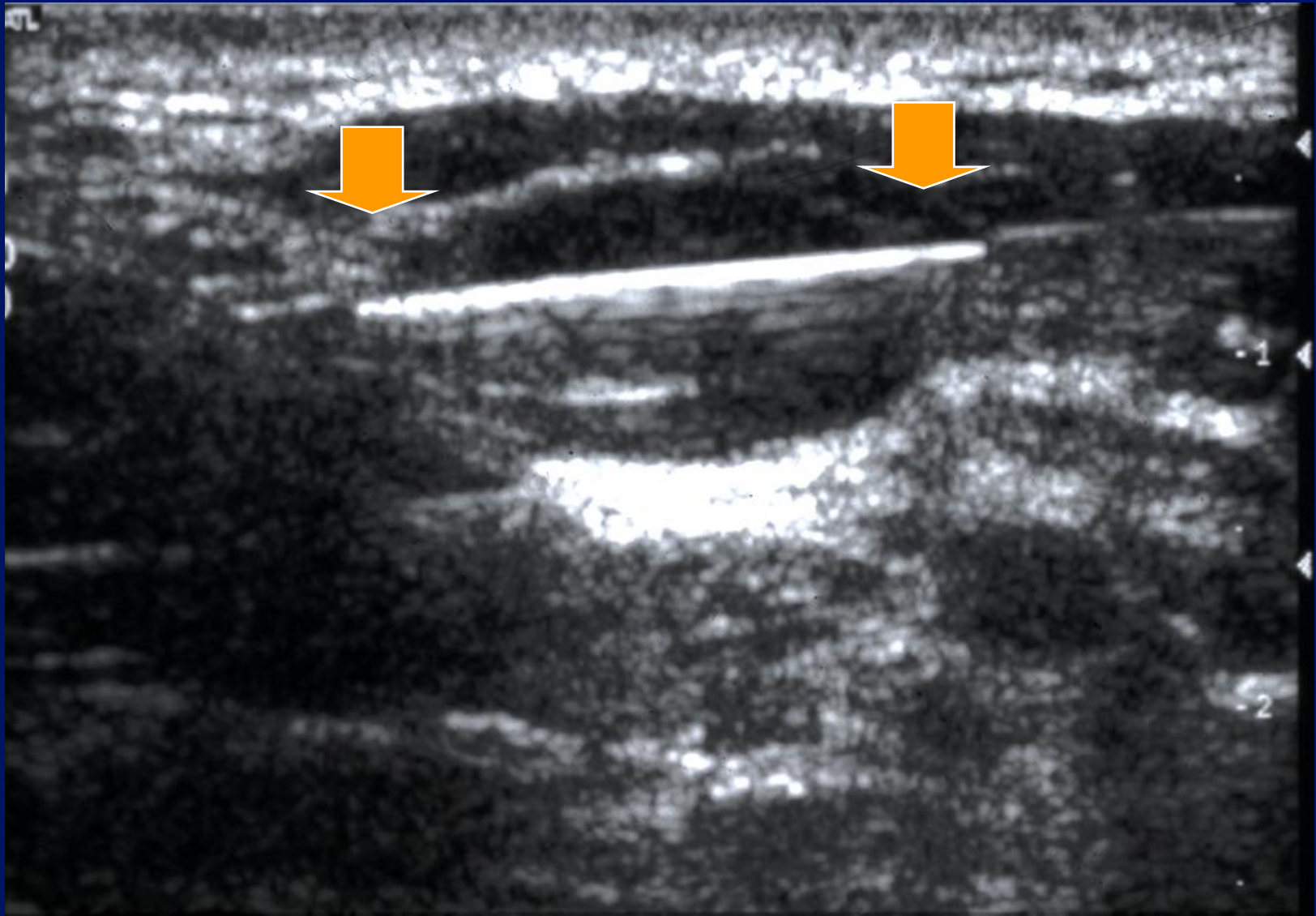


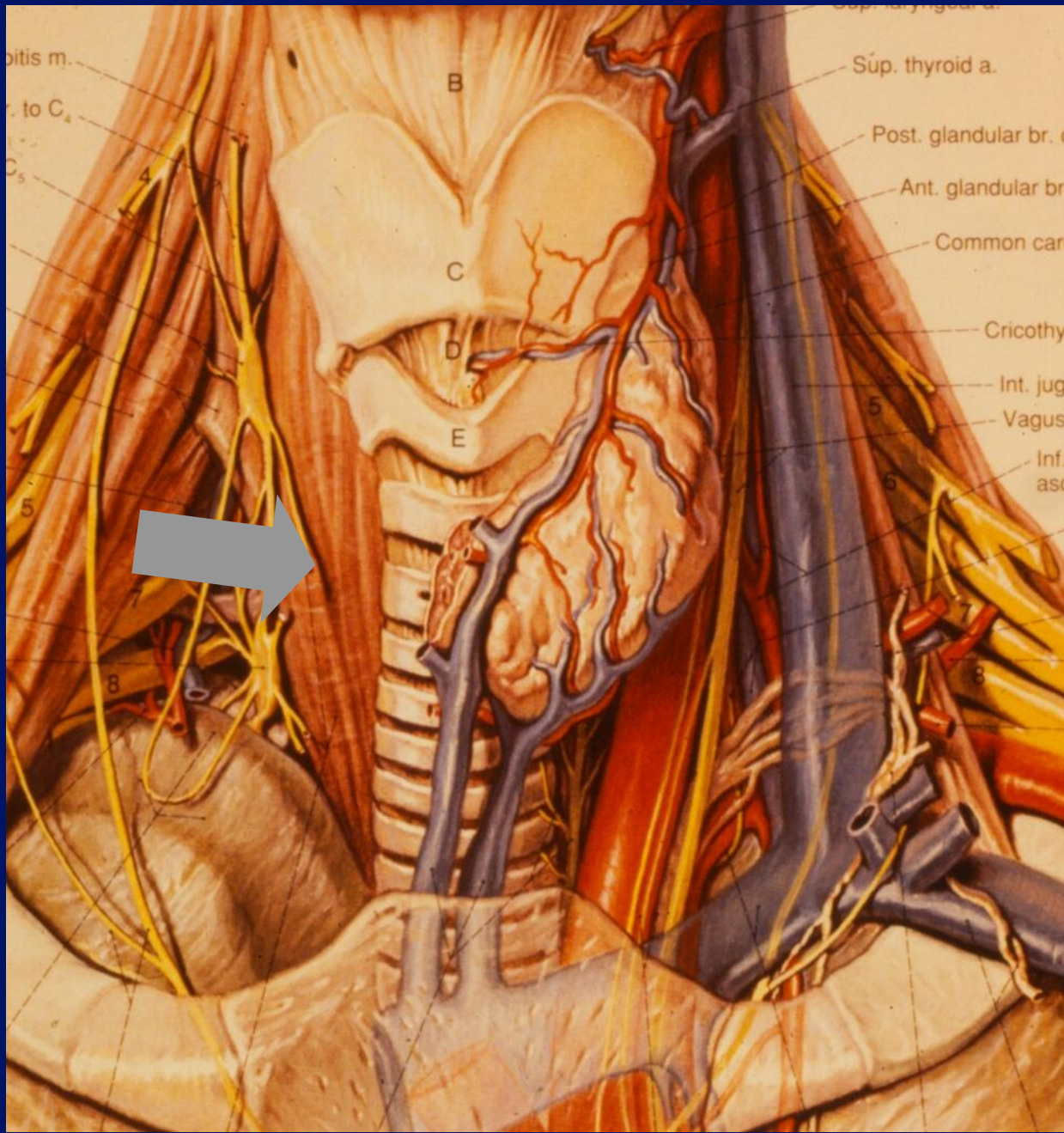




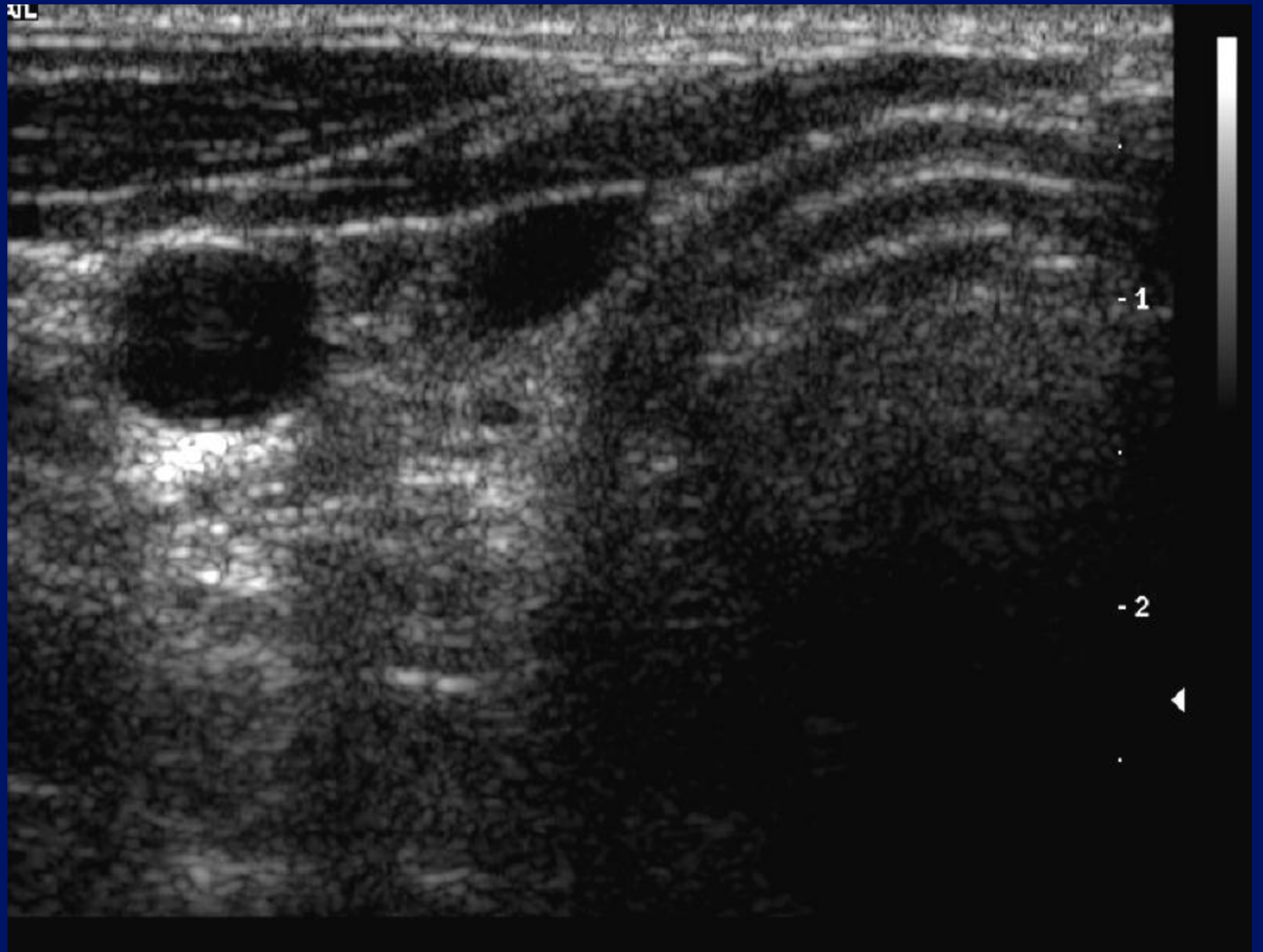




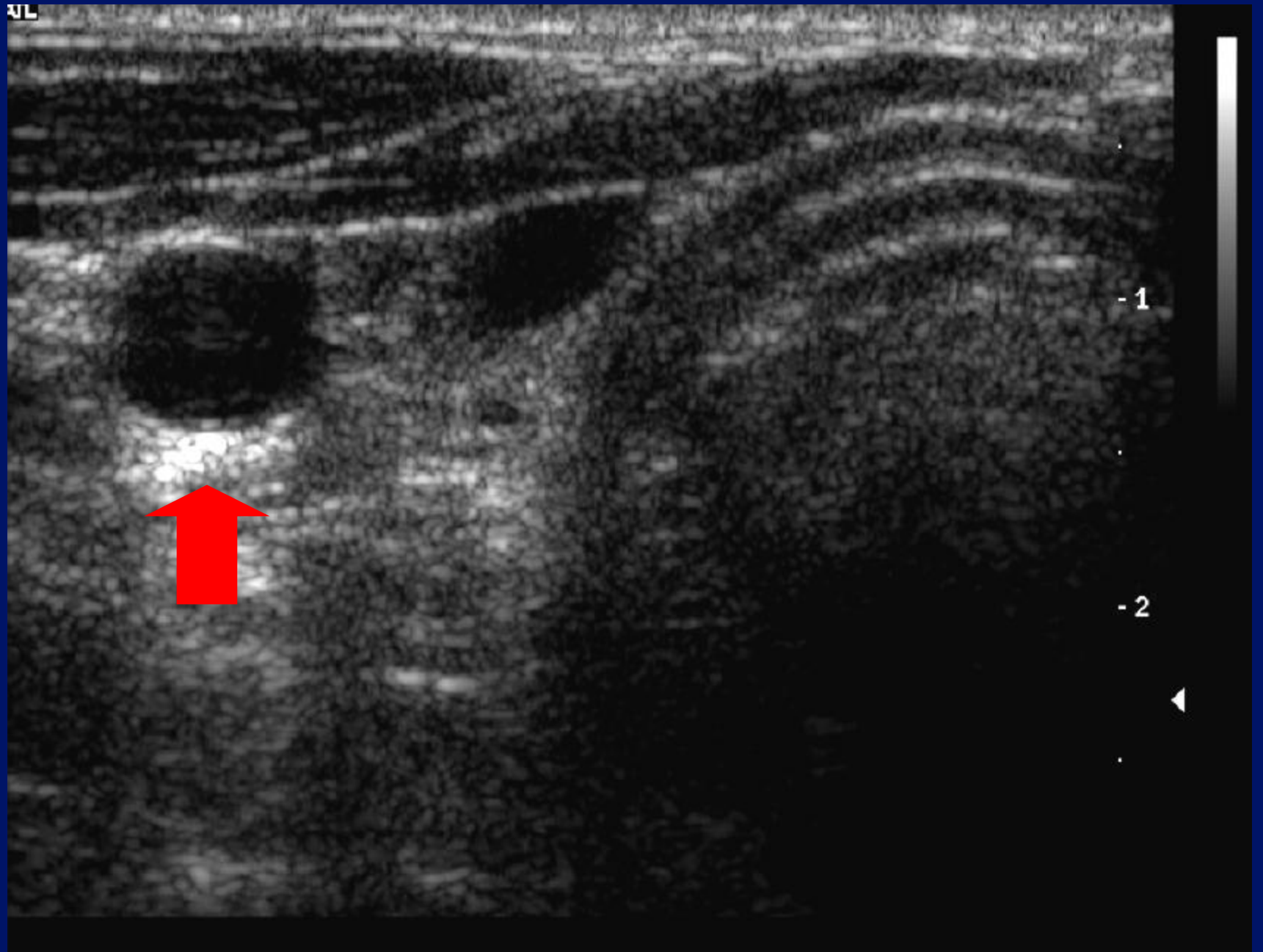




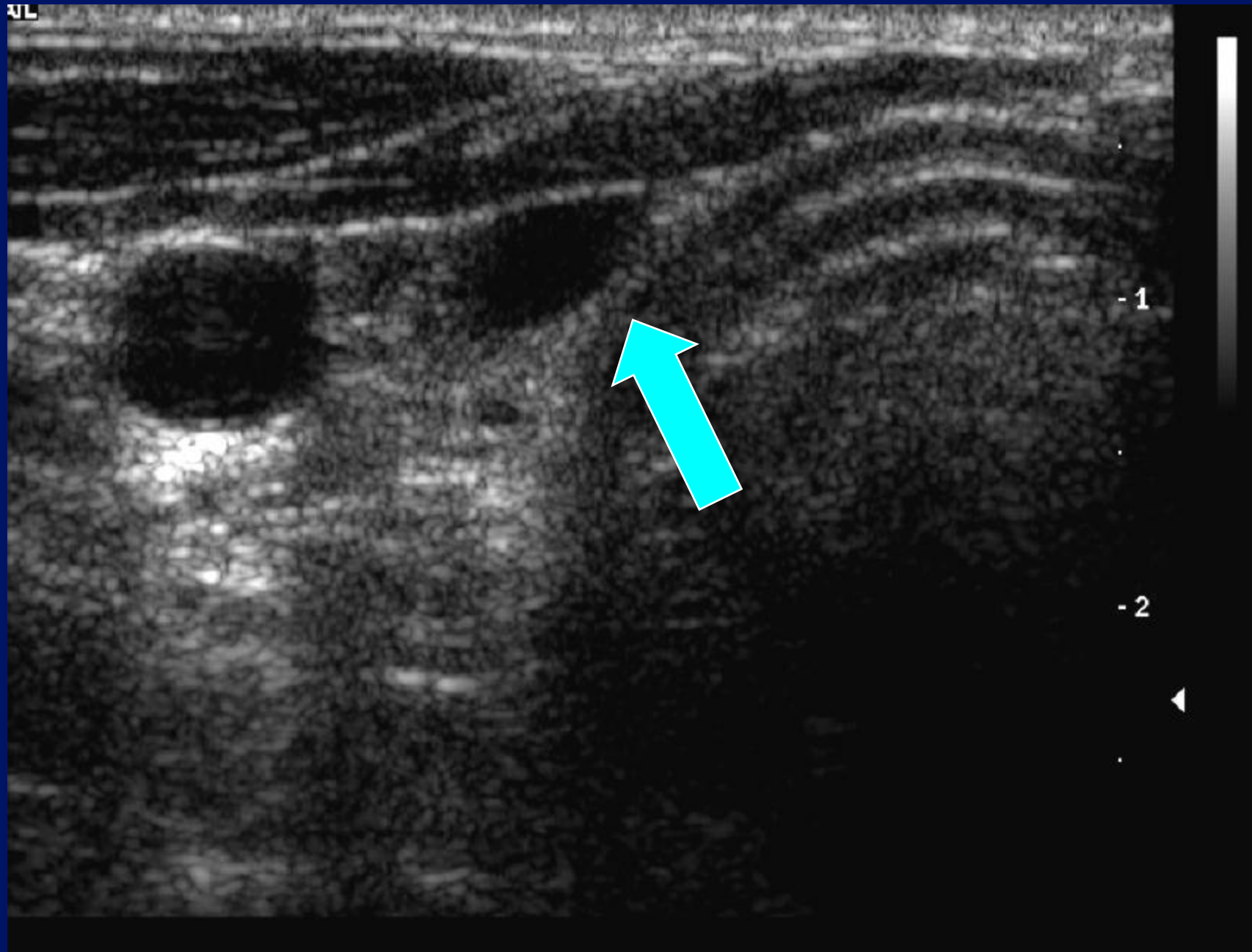
AL



AL



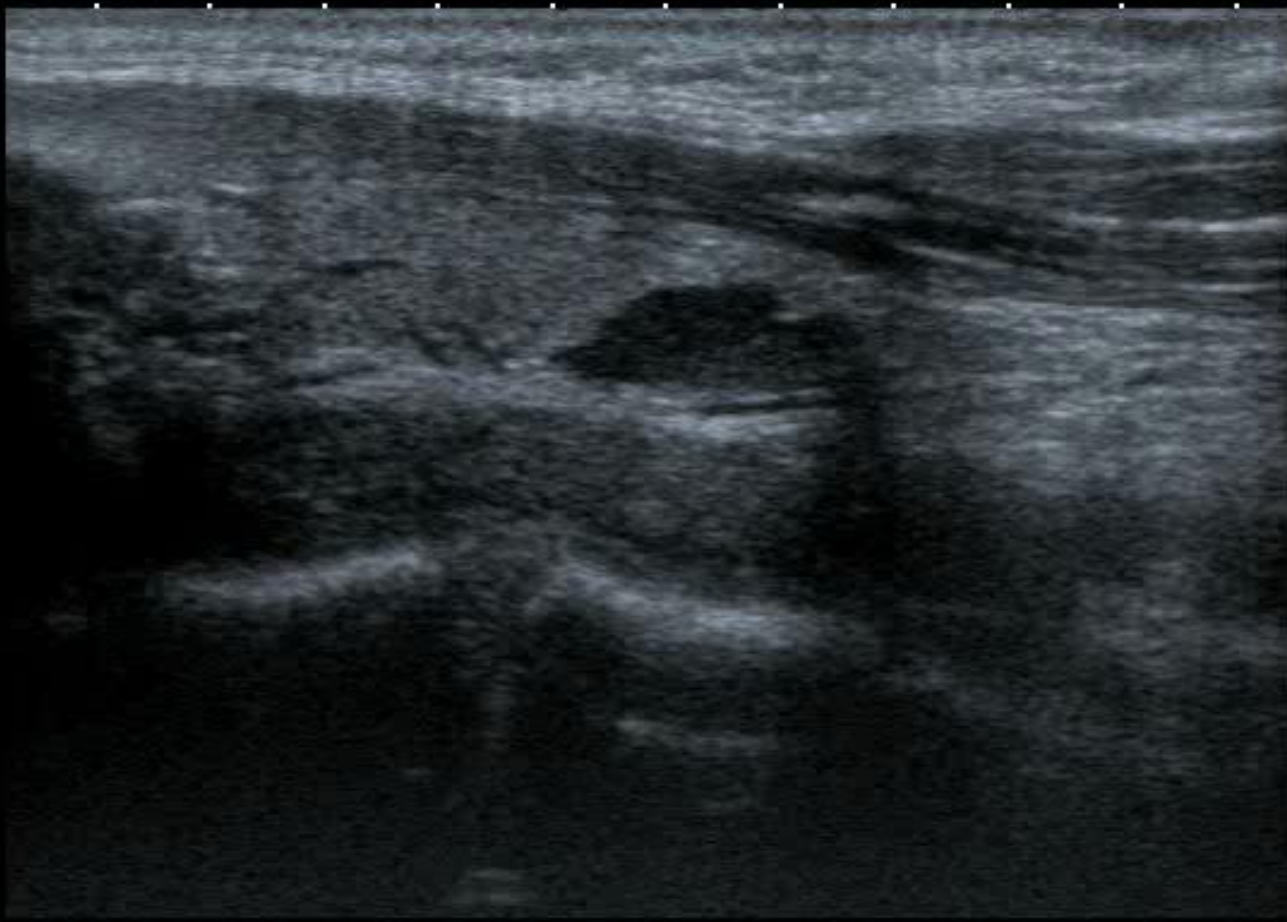AL



T
0 ◆
1 ◆
2 ◆
3 ◆
4 ◆

12L5
T9.0


18 fps



MI: 1.6
2DG
89
DR
70

Pseudo-cystic?

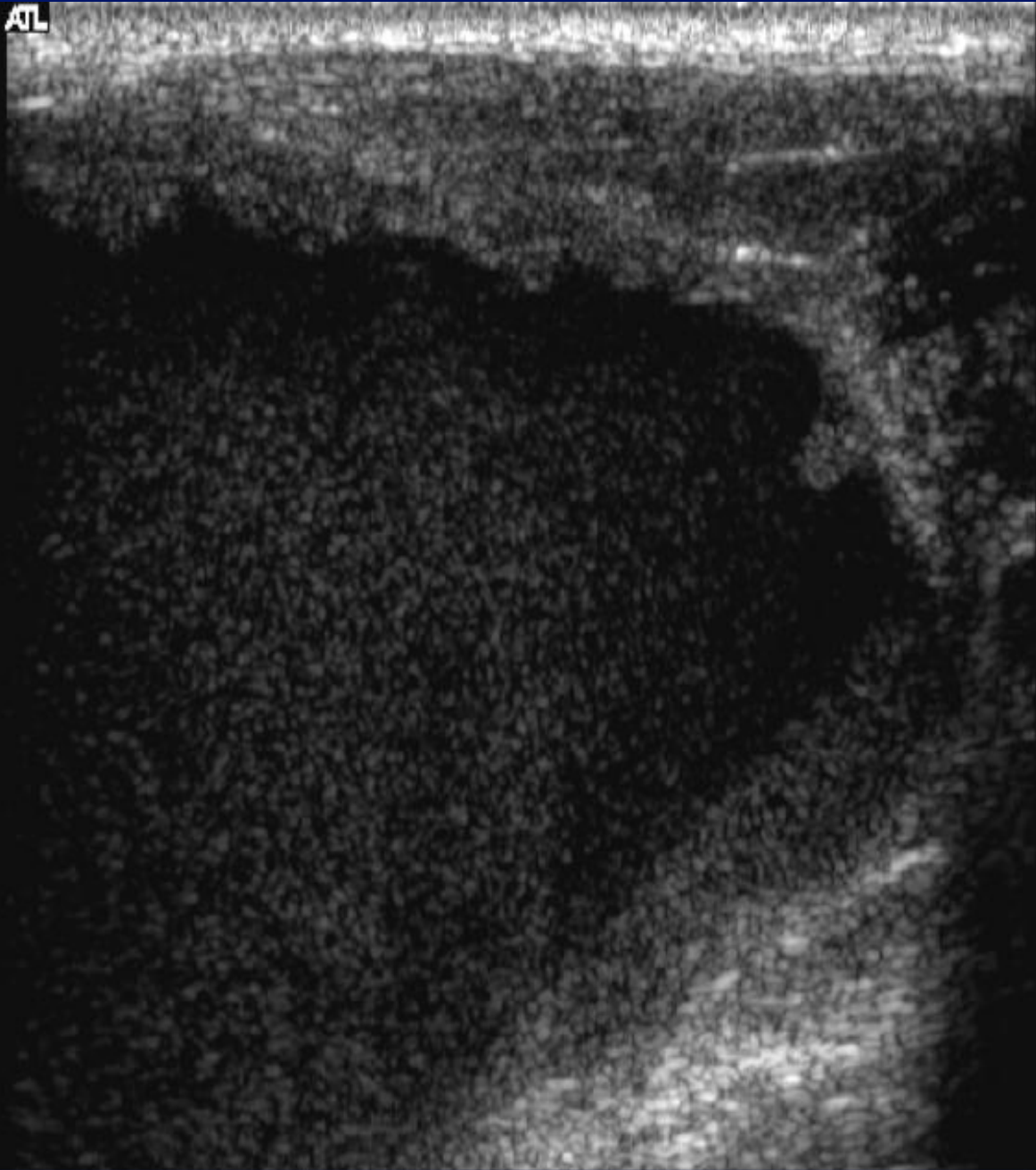
- Lymphoma.
- Pleomorphic adenoma.
- Nerve sheath tumour.
- Parathyroid adenoma.



Rules .

- Cysts don't usually look like cysts.
- Cysts will invariably look solid.
- If a mass looks cystic, it probably won't be a cyst.
- Solids can look cystic

ATL



-1

-2

-3



ATL

-1

-2

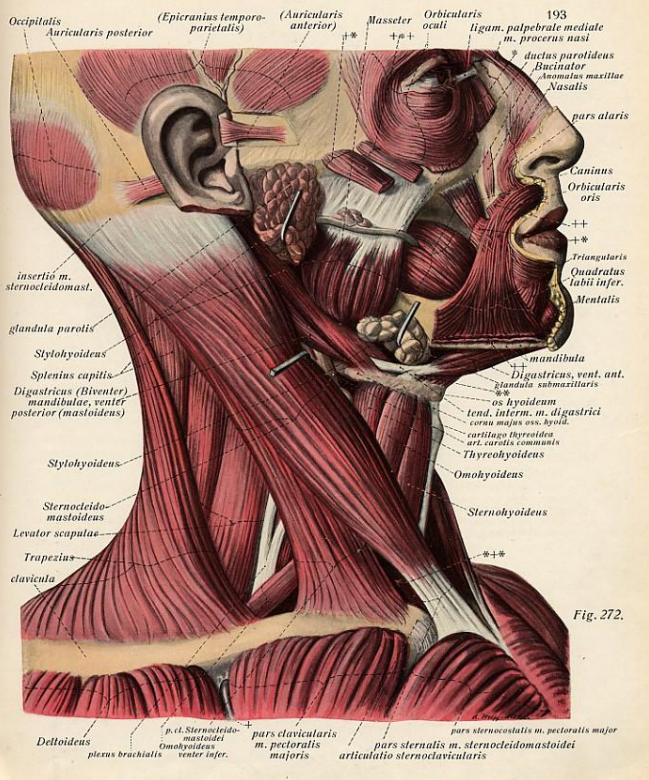
-3

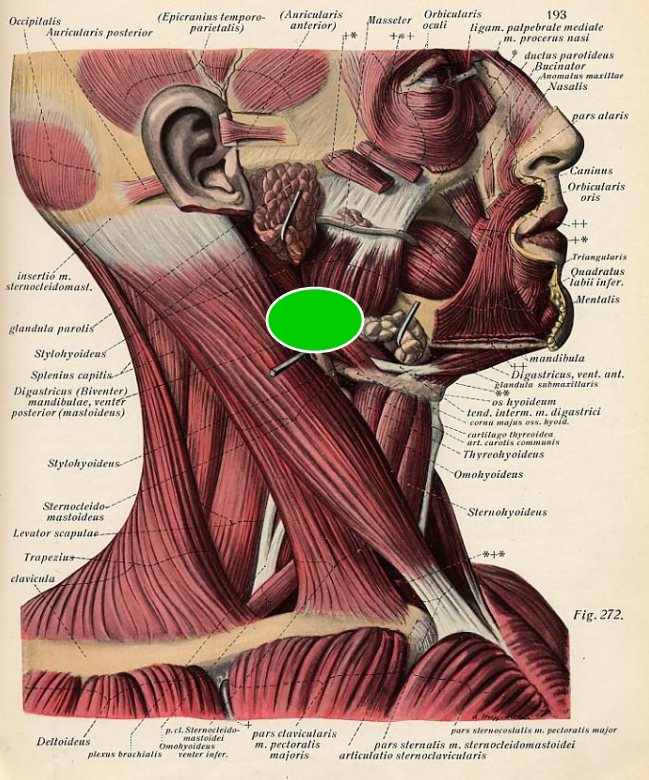


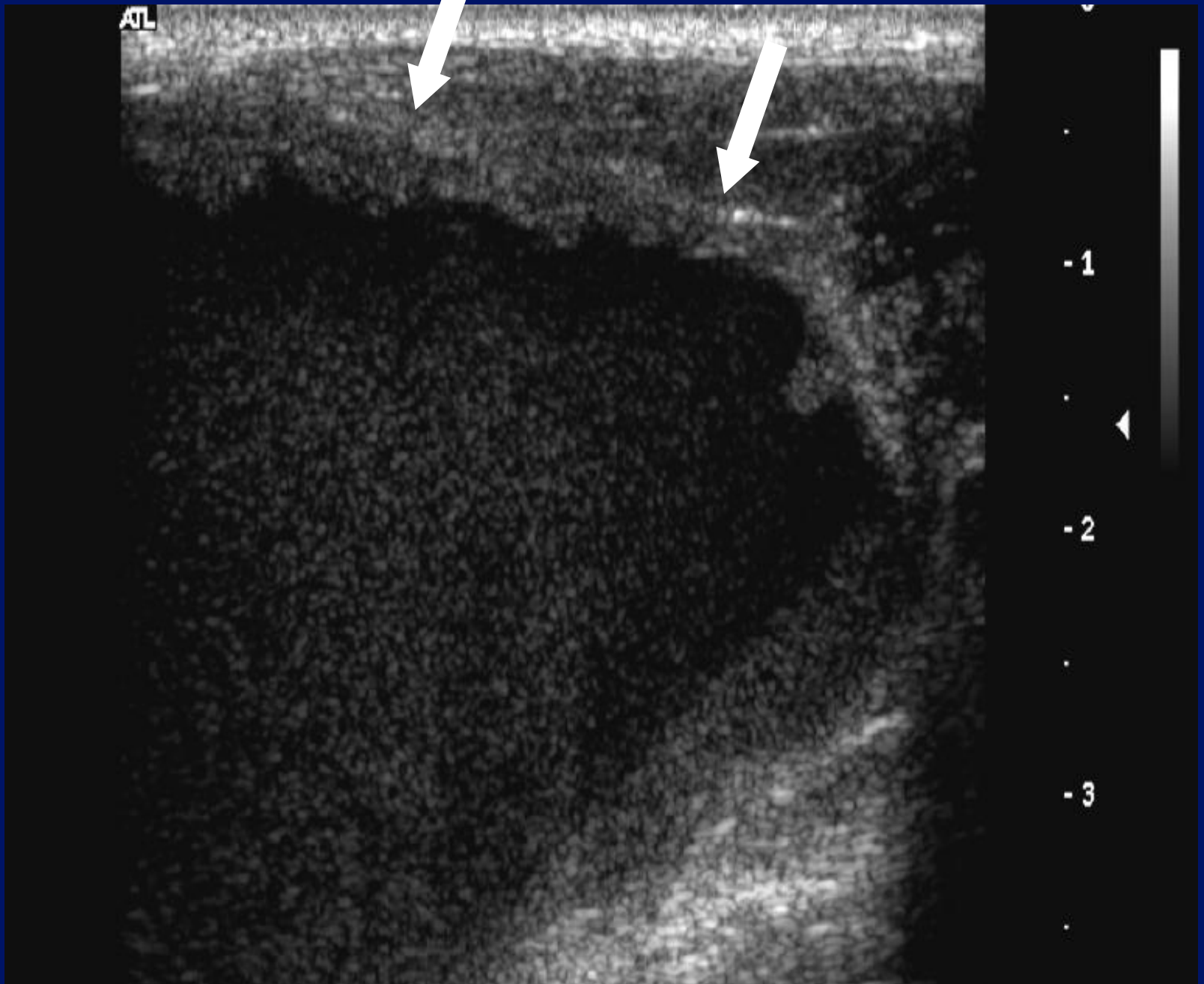
-1

-2

-3

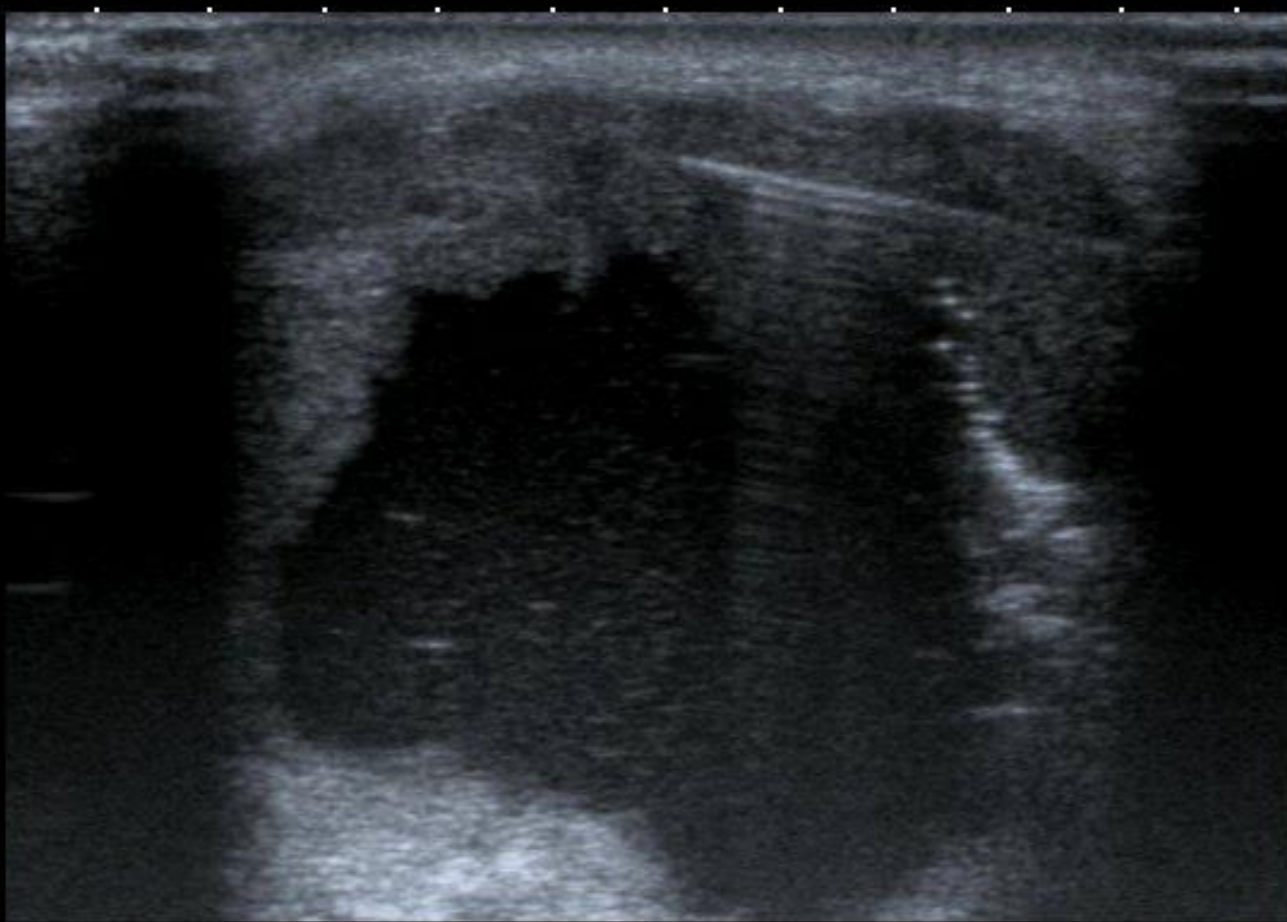








0 ♦
1 ♦
2 ♦
3 ♦
4 ♦

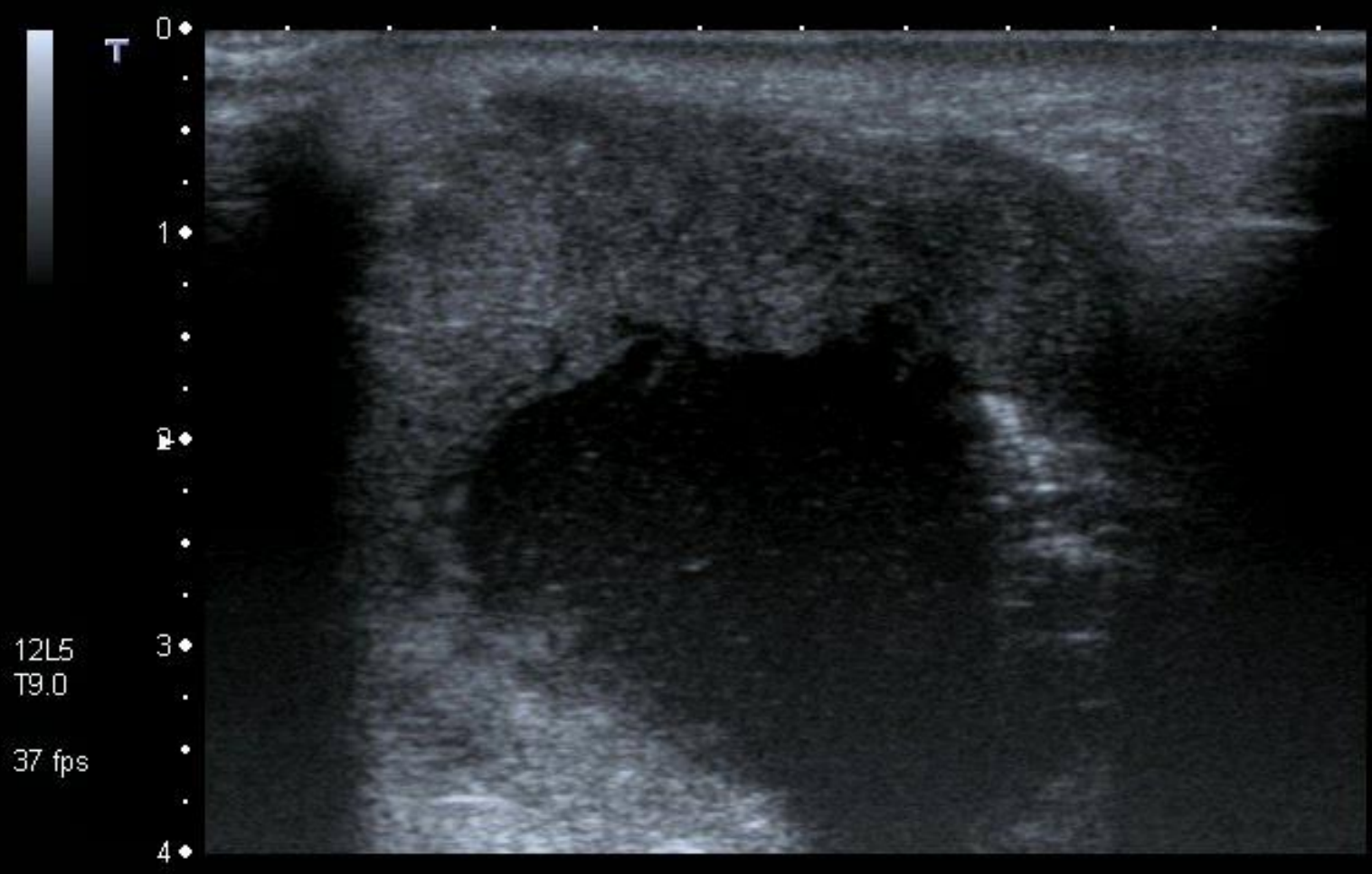


MI: 1.6
2DG
85
DR
70

12L5
T9.0

37 fps





12L5
T9.0
37 fps

MI: 1.6
2DG
85
DR
70

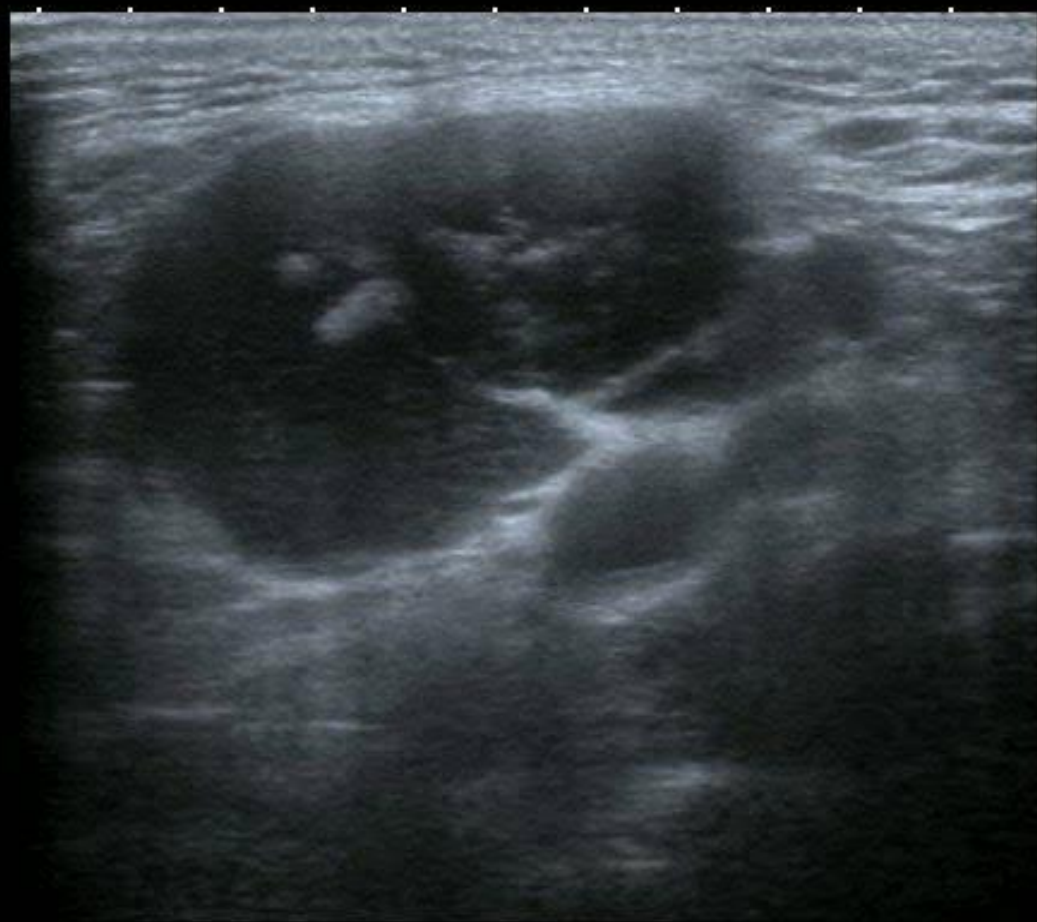



0 ◆

2 ◆ ▶

4 ◆



MI: 1.6

2DG
78

DR
65

12L5
diffT8.0

31 fps

A0 IP4

HDD: 73% Free

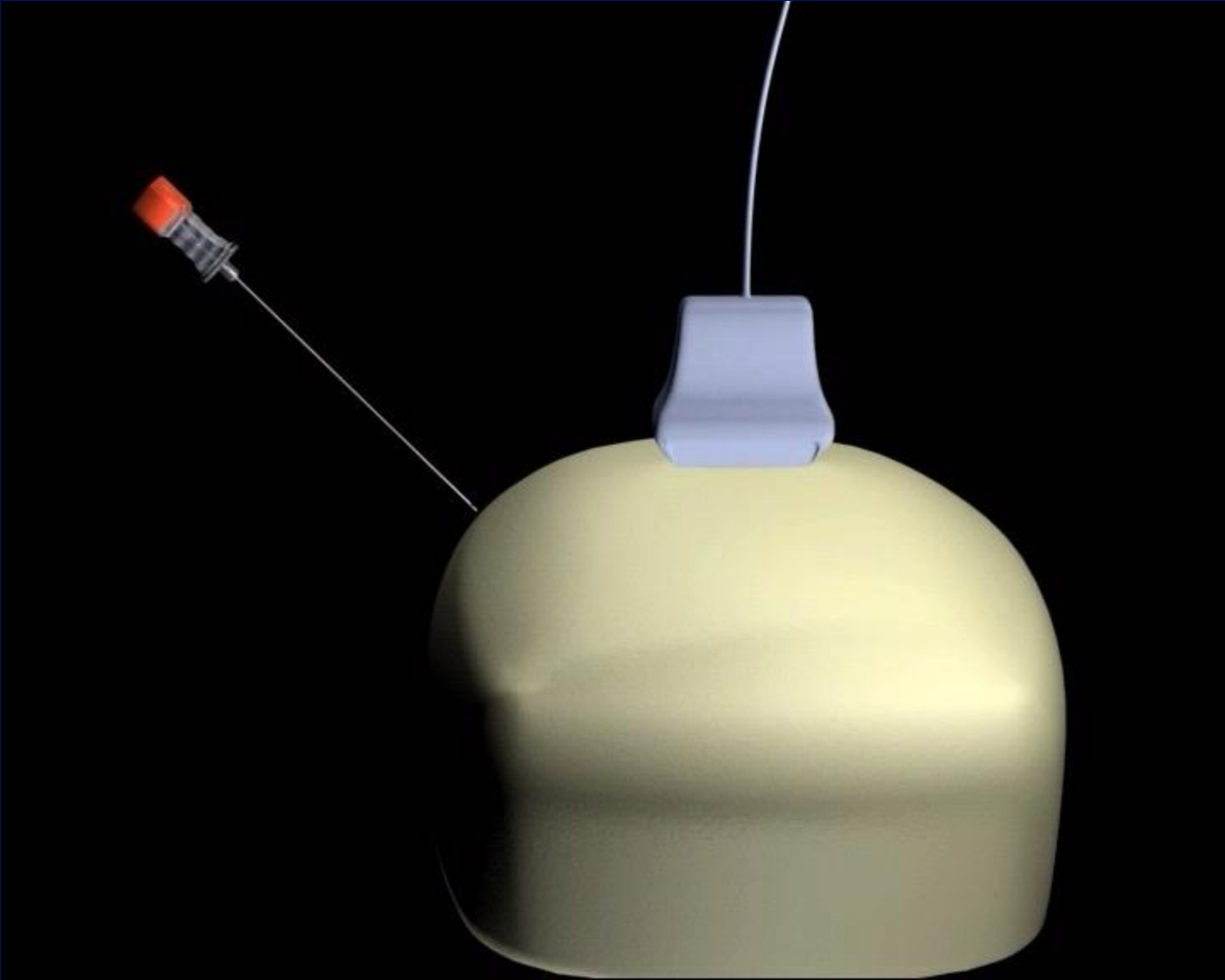


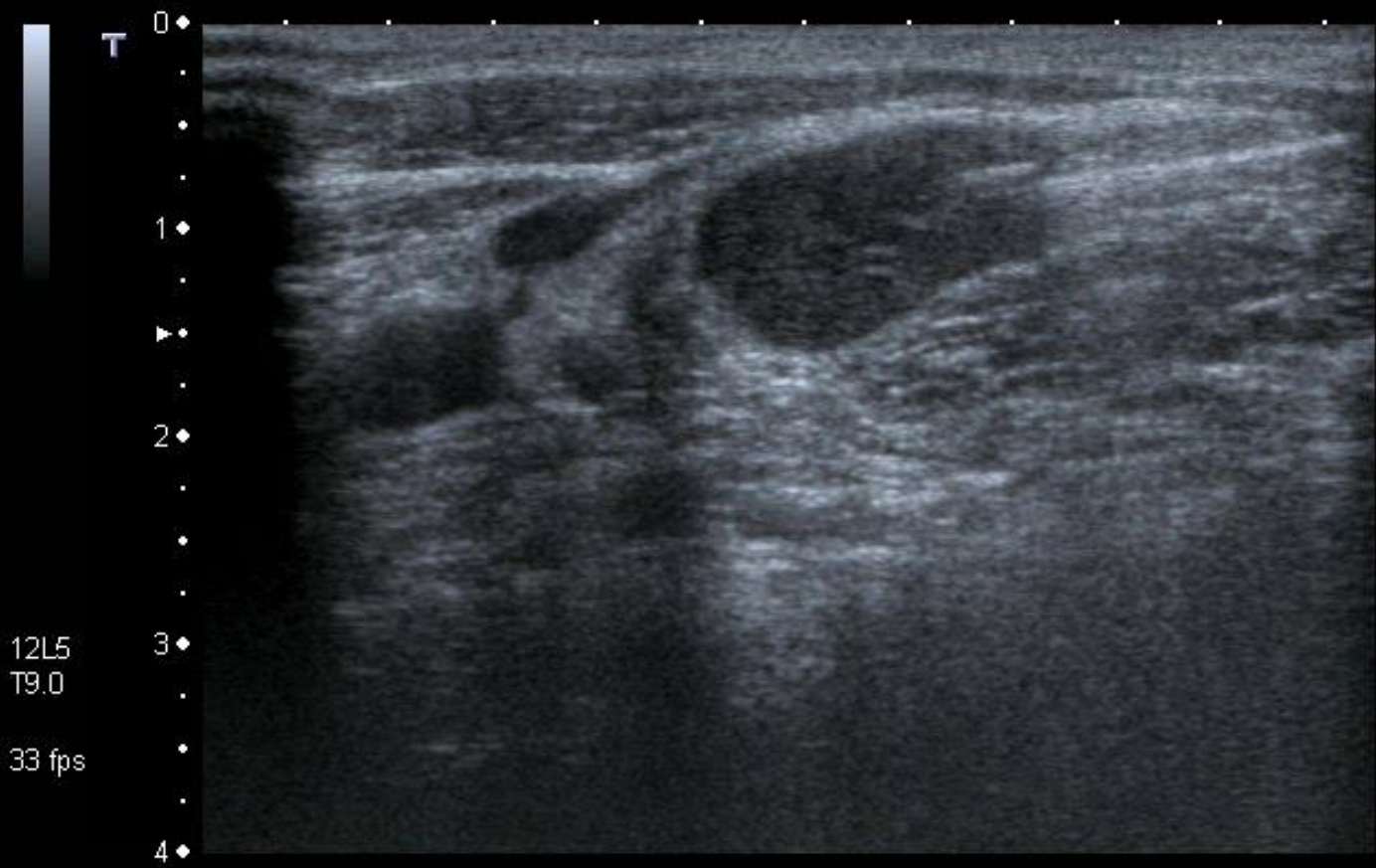
Cystic mass – upper cervical.

- Second Branchial cleft cyst.
- Metastatic lymph node : S.C.C.
- Metastatic lymph node : Papillary Carcinoma Thyroid .

Biopsy techniques

- Parallelism
- Needle
- Operator
- Monitor, brain and hands.

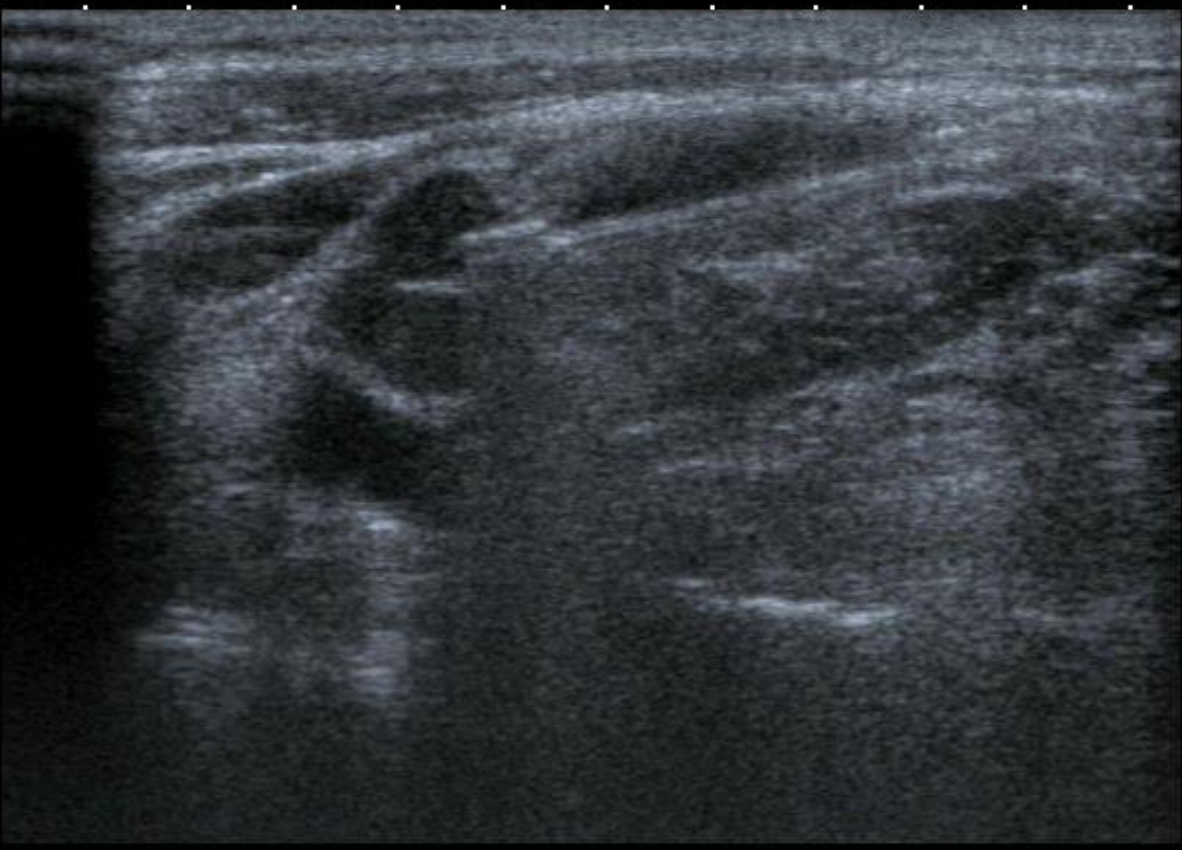



T
0
1
2
3
4

12L5
T9.0

33 fps



MI:1.6
2DG
80
DR
70



